

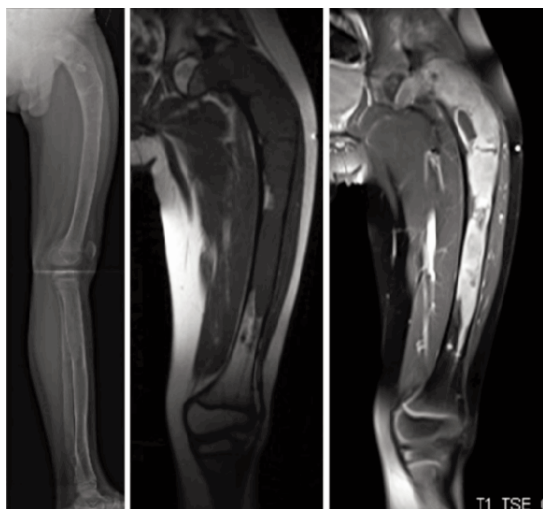
ORTHOPAEDIC CLINICAL QUIZ

The following questions are based on the photographs and images provided. Answers and further information are available in Page 78 & 79

Mansor A, Yasin NF, Ahmad TS

Department of Orthopaedic Surgery, University of Malaya, Kuala Lumpur, Malaysia

We would like to acknowledge the Conjoint Board of Orthopaedics Malaysia and contributors who have made this material available.



Question 1

The figures show plain radiograph and MRI images of the left femur.

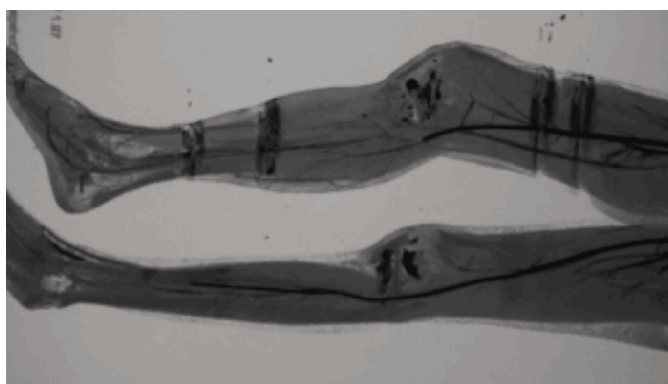
- List two abnormal findings in the radiograph. (2 marks)
- List two abnormal features in the MRI. (2 marks)
- State the diagnosis. (1 mark)
- List four clinical features associated with this condition. (4 marks)
- List one syndrome associated with this condition. (1 mark)

Question 2

This is an implant.



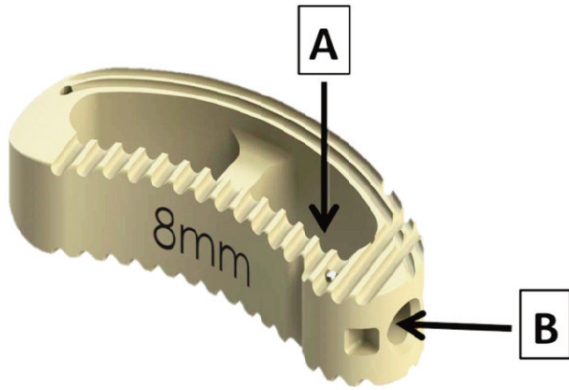
- State the relationship between implant diameter and torsional stiffness. (2 marks)
- Define 'Working Length' of this implant for the treatment of a transverse fracture. (2 marks)
- What is the relationship between torsional stiffness and working length? (2 marks)
- Give two intra-operative measures that would reduce the working length and give reason. (4 marks)



Question 3

This is an image of a 17-year-old girl who sustained a closed displaced tibial plateau fracture.

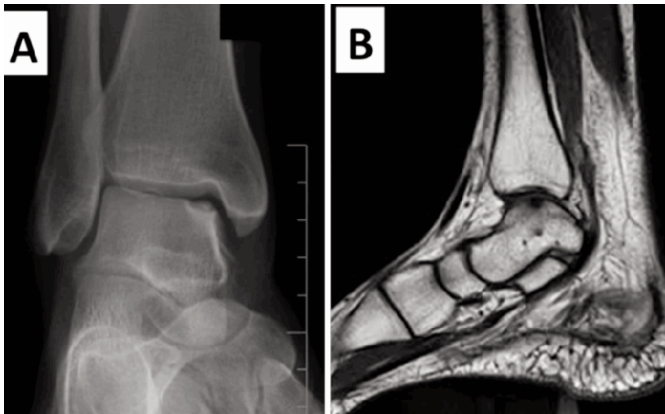
- Name the investigation. (2 marks)
- List three abnormal findings. (3 marks)
- List two possible causes for the vascular injury. (2 marks)
- List three immediate measures that should be done in the Emergency Department for this patient. (3 marks)



Question 4

The figure is an implant used in spine surgery.

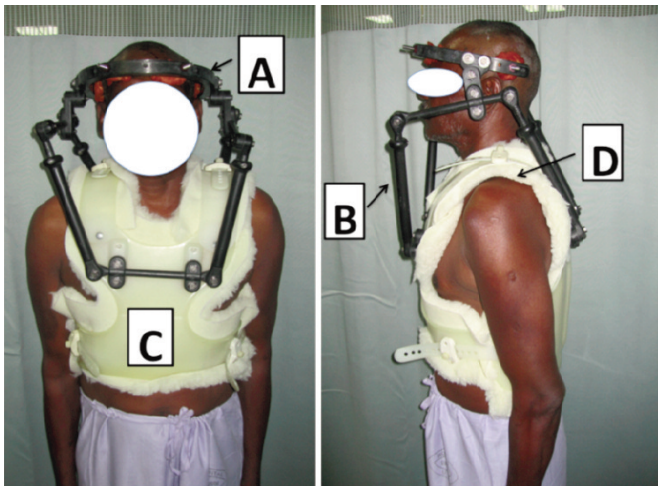
- Name the implant and the material it is made of. (2 marks)
- Name the parts labelled A and B. (2 marks)
- State two advantages of this implant. (2 marks)
- State four indications for its use. (4 marks)



Question 5

A 46-year-old female presented with right ankle pain for 8 months following a fall on her inverted foot. She was treated with ankle brace and physiotherapy; however, the pain persisted. A and B are the images taken prior to treatment.

- Describe the abnormal findings in A and B. (4 marks)
- What is the diagnosis? (1 mark)
- List three indications for conservative management. (3 marks)
- List two options for surgical treatment in this patient. (2 marks)



Question 6

This is a patient using an orthosis.

- Name the orthosis. (1 mark)
- State two indications for the orthosis. (2 marks)
- Name the parts labelled A,B, C and D. (4 marks)
- Name three nerves that can be injured when using this orthosis. (3 marks)