

Pneumothorax Complicating Clavicle Fractures In Newborns

Soong NJY, Chua WS

Orthopaedic Department, Hospital Duchess of Kent, KM 3.2, Jln Utara, Sandakan, 90000, Malaysia.

INTRODUCTION:

Clavicle fractures are fairly common during labour especially in difficult vaginal deliveries, shoulder dystocia or abnormal presentations in labour.¹ Spontaneous symptomatic pneumothorax are also rare at 0.05-0.07% of all newborn infants.⁴ Complications from clavicle fractures are uncommon, and with pneumothorax as a complication is even rarer.³ In this case study, we witnessed not one but two cases of isolated clavicle fractures complicated by pneumothorax requiring chest tube insertion.

CASE REPORT:

Baby A was 3.4 kg at term, delivered via vacuum assistance due to fetal distress. He was put on BiPAP in view of grunting. Subcutaneous emphysema was noted on the left chest and was diagnosed to have left clavicle fracture with pneumothorax. Chest tube was promptly inserted and a thorough examination found no neurovascular injury.

Baby B was 3.33kg at term, delivered via vacuum assistance due to fetal bradycardia. She was also put on BiPAP due to labored breathing. Her condition deteriorated and was discovered that she had a right clavicle fracture complicated with pneumothorax necessitating chest tube insertion. She too did not sustain any neurovascular injury from the fracture.

In both babies the pneumothorax resolved and fracture united spontaneously without fixation and no signs of brachial plexus injury noted.

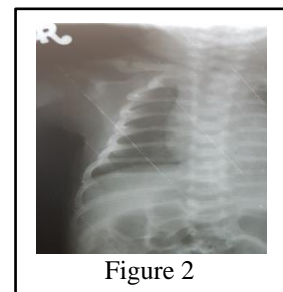
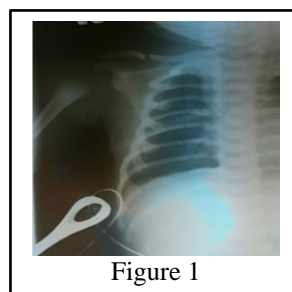
DISCUSSION:

Clavicle fractures in newborns are relatively common and well documented with an overall rate of 0.41-0.65%,^{1,2} and may go up to 3.41% in cases of instrument assisted deliveries.¹ Cases of clavicle fracture among newborns may sometimes be complicated with brachial plexus injury, about 1.6%, which usually have very good prognosis.² But those complicated by pneumothorax are almost unheard of among newborns, and among

adults only a limited number of cases were documented.³

These 2 cases are examples of rare complications arising which have to be diagnosed early and managed accordingly to treat the patients and improve the overall prognosis and ultimately resulting with favorable outcomes.

Figure 1: right clavicle fracture with chest tube in situ
Figure 2: 1 month post trauma with union of right clavicle resolved pneumothorax



REFERENCES:

1. LAI, Shui-Fan, Wai-Lam LAU, and Wing-Cheong LEUNG. "A Five-year Retrospective Study on Maternal Characteristics and Neonatal Outcomes of Clavicular Fractures in the Newborns: Another Piece of Reassurance."
2. Ahn, Eun Sub, et al. "Neonatal clavicular fracture: Recent 10 year study." *Pediatrics International* 57.1 (2015): 60-63.
3. P. Steenvoorde, A. P.W. VanLieshout, and J. Oskam, "Conservative treatment of a closed fracture of the clavicle complicated by pneumothorax: a case report," *Acta Orthopaedica Belgica*, vol. 71, no. 4, pp. 481-483, 2005.
4. Yu, V. Y., S. W. Liew, and N. R. Robertson. "Pneumothorax in the newborn. Changing pattern." *Archives of disease in childhood* 50.6 (1975): 449-453.