

Bipolar Hemiarthroplasty in Elderly Patients Presenting With Displaced Intracapsular Femoral Neck Fractures - A Comparison of Cemented and Uncemented Prosthesis Placement

H Krishnan, MS Ortho, **TR Yoon***, MD, **KS Park***, MD

Orthopaedic Department, Queen Elizabeth Hospital, Kota Kinabalu, Malaysia

*Center for Joint Disease, Chonnam National University Hwasun Hospital, Jeonnam, Korea

ABSTRACT

This retrospective study was undertaken to analyze perioperative parameters, functional outcomes and complications of cemented versus uncemented bipolar hemiarthroplasty in elderly patients presenting with displaced intracapsular femoral neck fracture. The authors reviewed 17 patients that underwent cemented bipolar hemiarthroplasty and 21 patients that underwent uncemented bipolar hemiarthroplasty. The mean follow-up duration in the cemented and uncemented group was 29.9 and 30.5 months respectively. Intraoperative and postoperative blood loss was higher in the cemented group. On the last follow-up the mean HHS was 74.7 in the cemented group and 84.2 in the uncemented group. No statistically significant difference was evident in the pain score. In summary, bipolar hemiarthroplasty was found to be a good option for displaced intracapsular femoral neck fractures, and overall outcome was marginally better in the uncemented group in terms of postoperative of blood loss and functional outcome at last follow up.

Key Words:

Displaced Intracapsular neck of Femur Fractures, Elderly Patient, Bipolar Hemiarthroplasty

INTRODUCTION

Hip fractures are among the most common injuries in elderly patients, and result in high rates of morbidity and mortality. Furthermore lengthening human longevity has led to an inevitable increase in the incidence of femoral neck fractures. However, the treatment of displaced femoral neck fractures in elderly patients is still controversial^{1, 17, 25, 27}. Some authors advocate reduction and fixation for these injuries, yet the literature shows unacceptably high rates of nonunion and osteonecrosis of the femoral head after internal fixation of femoral neck fracture in elderly^{1,17,19,21,22}. Although treatment of displaced intracapsular fracture by prosthetic replacement is a common procedure for elderly patients, the use of total hip arthroplasty (THA) presents a high risk of

dislocation in femoral neck fractures (up to 20%)^{23,24}. While Harjeet et al concluded that unipolar hemiarthroplasty is an efficacious and cost-effective treatment option for femoral neck fractures in the elderly, a meta-analysis by Lu-Yao reported that 6% to 18% of patients required a second surgery after unipolar hemiarthroplasty^{11,20}. Furthermore, in a long-term study, Soreide et al show that protrusion is a complication of unipolar hemiarthroplasty in 54% of cases studied²⁶. On the other hand, others with 4 years experience of bipolar prosthesis found no protrusion^{2,4}.

Due to the unsatisfactorily high level of uncertainty, this study was undertaken to analyze the relationship between perioperative parameters, functional outcome and complications of bipolar hemiarthroplasty in elderly patients with displaced intracapsular femoral neck fractures and to compare the clinical outcome between cemented and uncemented bipolar hemiarthroplasty.

MATERIALS AND METHODS

From January 2002 to July 2003, the authors performed 58 hemiarthroplasties for displaced intracapsular femoral neck fractures (Garden type IV & III). Thirty-eight of these patients were followed up for more than 24 months, while 20 were defaulted follow-up for unknown reasons. Inclusion criteria for this study were: age, >60 years; active and independently mobile life style; and, presentation with Garden type IV & III femoral neck fractures. Patients with a pathological fracture were excluded. All patients provided informed consent for participation in this study. Seventeen patients (4 males and 13 females, 12 Garden type IV and 5 Garden type III) underwent cemented bipolar hemiarthroplasty and 21 patients (5 males and 16 females, 17 Garden type IV and 4 Garden type III) underwent uncemented bipolar hemiarthroplasty. We retrospectively reviewed the patients and collected data from our hip surgery database. Mean age at time of surgery was 76.4y in the cemented group and 76.7y in the uncemented group. The mean duration of follow-up was 29.9 months in the cemented and 30.5 months in the uncemented group (Table I).

Table I: Clinical data, Perioperative results, Harris Hip Score And Pain Score

Parameter	Cemented	Uncemented	P-value
Patient data			
Age (yrs)	76.4(60-91)	76.7(60-87)	
Follow-up duration (months)	29.9 (24.8–49.5)	30.5 (24.7–59.8)	
Perioperative period			
Operation time (min)	46.8(30-75)	43.6(30-65)	0.586
Total blood loss (ml)	969.1(678-1587)	733.8(574-1316)	0.008†
Intraoperative blood loss	368.1(258-589)	280.6(215-421)	0.025†
Postoperative blood loss	601.0(420-998)	453.2(359-895)	0.012†
Last follow-up			
Harris hip score	74.7(39-100)	84.2(59-100)	0.012†
Pain*	2.5(1-4)	1.8(1-3)	0.067

* Using a 5-point scale in which: 1 signifies pain with extreme activity only; 2 signifies pain with moderate activity; 3 signifies pain with normal daily activity; 4 signifies pain at rest; and, 5 signifies pain at night that interferes with sleep
 †, Statistically significant

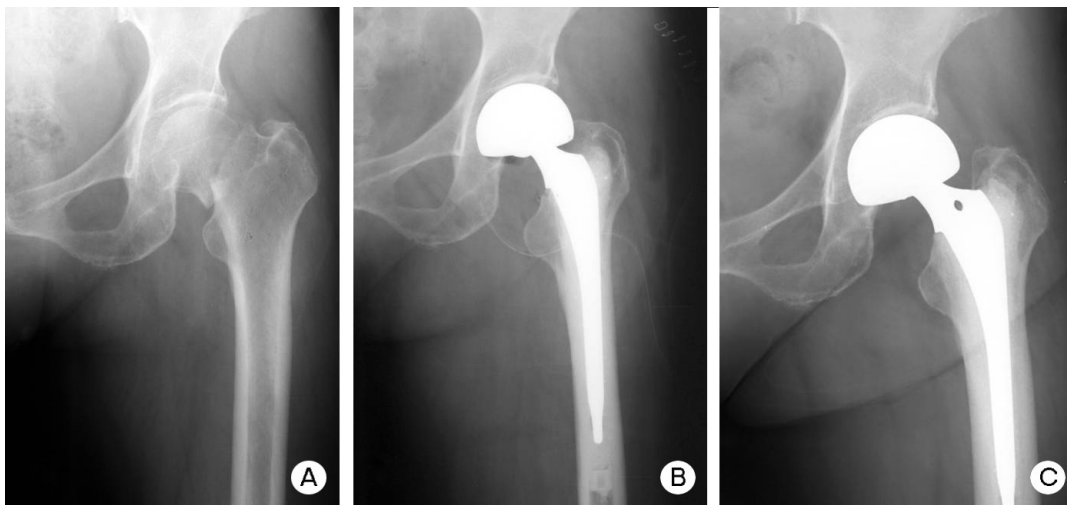


Fig. 1: (A) Preoperative radiograph of a 75 year-old female with left displaced femoral neck fracture. (B) Postoperative radiograph of cemented bipolar hemiarthroplasty via conventional posterolateral incision in same patient. (C) Radiograph taken 34 months postoperatively showing no loosening around femoral stem; the patient’s Harris hip score at this time was 83.

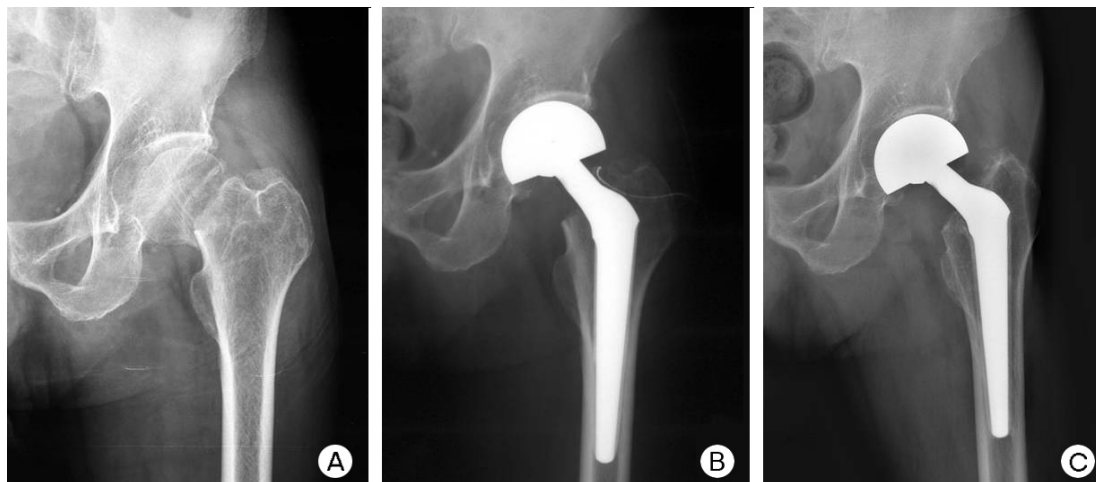


Fig. 2: (A) Preoperative radiograph of 80 year-old male with left displaced femoral neck fracture. (B) Postoperative radiograph of same patient after undergoing uncemented bipolar hemiarthroplasty via posterolateral mini-incision. (C) Radiograph taken 65 months postoperatively showing good bony integration; the patient’s Harris hip score at this time was 85.

Bipolar hemiarthroplasties were performed with the patient placed in the lateral position using a conventional posterior lateral approach in the cemented group and mini-incision posterolateral approach in the uncemented group. One surgeon, namely the author, performed all surgeries in this study. In the uncemented group, a longitudinal incision was made from 1 cm above the tip of the greater trochanter and extended proximally (most were mini-incisions at 7 to 8 cm long), whereas in the cemented group incisions were 12 to 14 cm in length (starting 1 cm distal from greater trochanter). Versys™ (Zimmer, Warsaw, USA) stems were used in the cemented group (Figure 1) and Cone Prosthesis™ (Zimmer, Winterthur, Switzerland) femoral stems without cementing were used in the uncemented group (Figure 2).

Prophylactic antibiotic were administered prior to skin incision and elastic stockings were used for one month postoperatively for deep vein thrombosis (DVT) prophylaxis; low molecular weight heparin was also administered for DVT prophylaxis until the patient start ambulating. Postoperative mobilization was achieved using a set protocol supervised by experienced orthopaedic physiotherapists. Early walking on crutches was allowed as tolerated from the first postoperative day.

The cemented and uncemented groups were compared with respect to intraoperative, postoperative and total blood loss and complications were compared. Patient's functional status at last follow-up were evaluated using the Harris hip score (HHS), and pain score¹². During radiological evaluation, acetabular erosion was checked in both hips in the anteroposterior view. Limb length discrepancies were determined by radiological comparison with distances between the upper margins of lesser trochanter to lines between both tear drops in the anteroposterior view (supine position). Varus and valgus alignment of femoral components was evaluated by Khalily and Lester's method and osteolysis of femoral components were assessed on anteroposterior and lateral radiographs using Gruen's classification^{10,15}. More than 3 degrees change and more than 2 mm location change without bony ingrowth around femoral component were considered as component subsidence. Statistical analysis was performed using the Mann-Whitney test in the SPSS software package (Version 13.0 SPSS Inc. Chicago, IL). p values of <0.05 were deemed significant.

RESULTS

The mean operative time for the cemented and uncemented groups were 47 minutes (30 to 75 minutes) and 44 minutes (30 to 65 minutes) respectively (p=0.286). The mean intraoperative blood loss in the two groups were 368 ml (258 to 589 ml) for the cemented group and 281 ml (215 to 421 ml) for the uncemented while (p=0.025) and mean

postoperative blood loss were 601 ml (420 to 998 ml) and 453 ml (359 to 895 ml) respectively (p=0.012).

At last follow-up, the mean HHS in the cemented group was 74.7 points (39 to 100 points), and in the uncemented group, 84.2 points (59 to 100 points) (p=0.012) while the mean pain score was 2.5 points (1 to 4 points) and 1.8 points (1 to 3 points) respectively (p=0.067) (Table I).

No intraoperative complication or postoperative dislocations occurred in either group. In the cemented group, there was one case of stem loosening 5 years postoperatively (stem revision performed), and in both groups acetabular erosion occurred in two patients 4 years postoperatively. In addition, one patient in the uncemented group suffered a periprosthetic fracture at 15 months after surgery and was treated with cable wiring.

DISCUSSION

In the present study, intraoperative blood loss (p=0.025), postoperative blood loss (p=0.012) and the mean operative time was lower in the uncemented group. Lo et al reported a similar finding but found that cemented prosthesis provided better functional and radiographic results¹⁸.

We attribute the fact that no dislocations occurred to the greater stability of the bipolar prosthesis (because of its biomechanically increased range of motion).[8] Dorr reported high dislocation rates in THA and cemented hemiarthroplasty when performed in femoral neck fractures; similarly Ravikumar found up to 20% dislocation rate in THA^{8,23}.

Despite decades of experience, the literature still does not give a clear and convincing overview of many issues concerning stem fixation in the treatment of this common orthopaedic problem. Emery in a randomized prospective trial found that the use of uncemented stems was associated with more hip pain and greater need for walking aids than cemented stems (when using Monk Duoplet Bipolar prosthesis with Thompson and Austin Moore stem)⁷. It was also found that the incidence of postoperative complications, early mortality, operating time, and blood loss were not significantly different for cemented and uncemented prosthesis⁷. In the present study, however, there was no statistically significant difference in operating time but blood loss was lower in the uncemented group.

Overgaard reported that 4 of 62 patients, a relatively small proportion, complained of pain with weight-bearing 6 years after uncemented bipolar hemiarthroplasty²¹. In the present study the HHS was better in the uncemented group and no significant difference was found in pain scores but this may be due to the minimally invasive technique used herein,

which probably reduced soft tissue and muscle damage as well as scarring. Furthermore, no patient in the present study had pain during normal activities at follow-up, which is comparable to the Goldhill study in which study subjects with bipolar prosthesis for fracture femoral neck were found to have occasional or slight pain⁹.

The only report in the English literature at the time of producing this manuscript of minimally invasive surgery for bipolar hemiarthroplasty is by Kaneko et al, who compared mini-incision (approximately 7cm in length) and ordinary incision bipolar hemiarthroplasty¹³. The general consensus, however, appear to be that cemented bipolar hemiarthroplasty is preferred for intracapsular femoral neck fracture, because it results in lower pain score postoperatively^{5,7}. Kenzora, in a prospective outcome study, concluded that the use of bipolar prosthesis (either a press fit or cemented) provided better pain relief and function and a lower complication rate than uncemented unipolar prosthesis albeit at higher cost¹⁴.

All the patients in this study were elderly (mean age: 76.4y for cemented group; 76.7y for uncemented group at time of surgery) and all femurs were osteoporotic. Thus, careful placement of the Hohmann retractor on the proximal femur and gentle elevation of the proximal femur for femoral reaming and stem insertion was important to avoid intraoperative fractures. We experienced no intraoperative periprosthetic fracture in either group but one case of periprosthetic fracture, 15 months postoperatively in the uncemented group as the patient slipped and fell on a slippery floor; this patient was treated by cable wiring and the fracture has since united. Although, Chandran reported a rate of 7.4% for intraoperative periprosthetic fractures for uncemented bipolar prosthesis, these occurred while attempting to secure a tight fitting uncemented stem³. In the present study, four cases of acetabular erosion were encountered (two in each group), which is comparable to rates reported by Devas et al and one case of stem loosening in the cemented group due to technical error⁴.

The present study has several limitations that require consideration. First, it was a retrospective case controlled study rather than a prospective randomized controlled study. Second, the number of the cases included was small but the

sample size was sufficient when the power of hypothesis was fixed at 80% and the level of significance at 5%, according to Lehr's formulae¹⁶. Third, in the cemented group, patients with femoral neck fractures were treated with the Versys™ (Zimmer, Warsaw, USA) femoral stem, while in the uncemented group the Cone Prosthesis™ (Zimmer, Winterthur, Switzerland) femoral stem was used; thus, we cannot comment on the longevity of implants in this study. Furthermore as cementing involves additional operative time, blood loss levels would be thus influenced. Fourth, a different soft tissue approach was used in the cemented group, (conventional posterolateral approach) compared to the uncemented group (minimally invasive posterolateral approach) and thus, reduced soft tissue damage, muscle damage and scarring may have improved the HSS and pain scores. In addition, the pre-morbid activity level of the patients was not considered –the HHS score and a 5-point pain scale pain were used to evaluate clinical and functional outcomes. Other scoring systems were hard to apply in this study because the patients were elderly and it was difficult to get proper responses to the other types of questions. Lastly, the mean follow-up time was 29.9 months in the cemented group and 30.5 months in uncemented group, which is not enough for evaluation of protusio acetabuli.

CONCLUSION

From our relatively short-term retrospective nonrandomized study, we conclude that bipolar hemiarthroplasty produces good functional outcomes with minimal complications for displaced intracapsular femoral neck fractures and has several advantages; these results are comparable to the other studies. In the present study, overall outcomes were marginally better in the uncemented prosthesis group in which the mini-incision posterolateral approach was used compared to the cemented prosthesis operated group (conventional posterolateral approach) in terms of amount of blood loss and HHS on last follow up.

ACKNOWLEDGEMENT

The authors declare that they have no proprietary, commercial or financial interests that could be construed to have inappropriately influenced this study.

REFERENCES

1. Asnis SE, Wanek-Sgaglione L. Intracapsular fractures of the femoral neck: Results of cannulated screw fixation. *J Bone Joint Surg Am.* 1994; 76:1793-803.
2. Bochner RM, Pellicci PM, Lyden JP. Bipolar hemiarthroplasty for fracture of the femoral neck. Clinical review with special emphasis on prosthetic motion. *J Bone Joint Surg Am.* 1988; 70: 1001-10.
3. Chandran P, Kamath RP, Johnson GV. Intraoperative fractures during Furlong bipolar hemiarthroplasty. *Eur J Orthop Surg Traumatol.* 2007; 17: 273-7.
4. Devas M, Hinves B. Prevention of acetabular erosion after hemiarthroplasty for fracture neck of femur. *J Bone Joint Surg Br.* 1983; 65: 548-51
5. Dixon S, Bannister G. Cemented bipolar hemiarthroplasty for displaced intracapsular fracture in the mobile active elderly patient. *Injury.* 2004; 35: 152-6.
6. Dorr LD, Glousman R, Hoy AL, Vanis R, Chandler R. Treatment of femoral neck fractures with total hip replacement versus cemented and noncemented hemiarthroplasty. *J Arthroplasty.* 1986; 1: 21-8.
7. Emery RJH, Broughton NS, Desai K, Bulstrode CJK, Thomas TL. Bipolar Hemiarthroplasty For Subcapital Fracture Of the Femoral Neck. A Prospective Randomised Trial of Cemented Thompson and Uncemented Moore Stems. *J Bone Joint Surg Br.* 1991; 73: 322-4.
8. Giliberty RP. Bipolar endoprosthesis minimizes protrusion acetabuli, loose stems. *Orthop Rev.* 1985; 14:27.
9. Goldhill VB, Lyden JP, Cornell CN, Bochner RM. Bipolar Hemiarthroplasty for fracture of the femoral neck. *J Orthop Trauma.* 1991; 5: 318-24.
10. Gruen TA, McNeice GM, Amstutz HC. "Modes of failure" of cemented stem-type femoral components: a radiographic analysis of loosening. *Clin Orthop Relat Res.* 1979; 141: 17-27.
11. Harjeet S, Suhail A, Shahril Y, Masbah O, Subanesh S. Outcome of traumatic intracapsular neck of femur fractures in patients aged above 60 years treated by hemiarthroplasty for fracture of the femoral neck. *M Orthop J.* 2009; 1: 24-7.
12. Harris WH. Traumatic arthritis of the hip after dislocation and acetabular fractures: treatment by mold arthroplasty. An end-result study using a new method of result evaluation. *J Bone Joint Surg Am.* 1969; 51: 737-55.
13. Kaneko K, Mogami A, Ohbayashi O, Okkahara H, Iwase H, Kurosawa H. Minimally invasive hemiarthroplasty in femoral neck fractures: randomized comparison between a mini-incision and an ordinary incision: preliminary results. *Eur J Orthop Surg Traumatol.* 2005; 15: 19-22.
14. Kenzora JE, Magaziner J, Hudson J, Hebel JR, Young Y, Hawkes W, Felsenthal G, Zimmerman SI, Provenzano G. Outcome after hemiarthroplasty for femoral neck fractures in the elderly. *Clin Orthop Relat Res.* 1998; 348: 51-8.
15. Khalily C, Lester DK. Results of a tapered cementless femoral stem implanted in varus. *J Arthroplasty.* 2002; 17: 463-6.
16. Lehr R. Sixteen S-squared over D-square; a relation for crude sample size estimates. *Stat Med.* 2004; 11:1099-1102.
17. Levine AM. Orthopedic knowledge update: Trauma. *Am Acad Orthop Surg.* 1996; 1:113-9.
18. Lo WH, Chen WM, Huang CK, Chen TH, Chiu FY, Chen CM. Bateman Bipolar Hemiarthroplasty for displaced intracapsular femoral neck fractures uncemented versus cemented. *Clin Orthop Relat Res.* 1994; 302: 75-82.
19. Livesley PJ, Srivastava VM, Needoff M, Prince HG, Moulton AM. Use of a hydroxyapatite-coated hemiarthroplasty in the management of subcapital fractures of the femur. *Injury.* 1993; 24: 236-40.
20. Lu-Yao GL, Keller RB, Littenberg B, Wennberg JE. Outcomes after Displaced Fractures of the Femoral Neck. A meta-analysis of hundred and six published reports. *J Bone Joint Surg Am.* 1994; 76: 15-25.
21. Overgaard S, Jensen TT, Bonde G, Mossing NB. The uncemented bipolar hemiarthroplasty for displaced femoral neck fractures. 6 years follow-up of 171 cases. *Acta Orthop Scand.* 1991; 62: 115-20.
22. Rae PJ, Hodgkinson JP, Meadows TH, Davies DRA, Hargadon EJ. Treatment of displaced subcapital fractures with the Charnley-Hastings hemiarthroplasty. *J Bone Joint Surg Br.* 1989; 71: 478-92.
23. Ravikumar KJ, Marsh G. Internal fixation vs hemiarthroplasty vs total hip arthroplasty for displaced subcapital fractures of femur – 13 year results of a prospective randomized study. *Injury.* 2000; 31:793-797.

24. Sim R. Displaced femoral neck fractures: the rationale for primary total hip replacement. In: *The Hip: Proceedings of the Eleventh Open Scientific Meeting for Hip Society*, St Louis: CV Mosby; 1983: p.51.
25. Swiontkowski MF. Current concepts review: Intracapsular fractures of the hip. *J Bone Joint Surg Am.* 1994; 76:129–138.
26. Søreide O, Alho A, Riitti D. Internal fixation versus endoprosthesis in the treatment of femoral neck fracture in the elderly. A prospective analysis of the comparative costs and consumption of hospital resources. *Acta Orthop Scand.* 1980; 51: 827-31.
27. Majernicek M, Dungal P, Kolman J, Vaculik J. Osteosynthesis of intracapsular femoral neck fractures by dynamic hip screw (DHS) fixation. *Acta Chir Orthop Traumatol Cech.* 2009; 76: 319-25.