# Anatomical Considerations in the Utilisation of Minimally Invasive Cerclage Wiring for Femoral Fracture Fixation

**Ng SWL**[1], FRCS (Edin), **Tan QH**[2], MBBS, **Chong LR**[3], FRANZCR, **Kam CJW**[4], MSc (Stat), **Yeo AKS**[2], FRCS (Edin)

[1]Department of Orthopaedic Surgery, KK Women's and Children's Hospital, Singapore
[2]Department of Orthopaedic Surgery, Changi General Hospital, Singapore
[3]Department of Diagnostic Radiology, Changi General Hospital, Singapore
[4]Department of Clinical Trials and Research, Changi General Hospital, Singapore



Date of submission: 07th June 2025
Date of acceptance: 01st October 2025

## ABSTRACT

**Introduction:** Cerclage wiring remains a popular reduction tool in managing complex fractures of the femur. We propose that the direction in which the minimally-invasive wire passer (MI-WP) is inserted should be considered distinct from that of the conventional wire passer to minimise vessel injury.
**Materials and methods:** The computed-tomographic angiograms of 101 limbs from 78 unique patients from 2010 to 2017 were reviewed. We identified three common levels of wiring: the lesser trochanter (LT), midshaft of the femur, and the adductor tubercle. The position of and the shortest distance from the outer cortex of the femur to the superficial femoral artery (SFA) and the profunda femoris artery (PFA) at these levels were recorded.
**Results:** The mean distance of the SFA to the LT and femur midshaft was 6.8mm further in a male compared to a female ($p<0.001$). Males showed a significantly further distance from the PFA to the LT and femur midshaft ($p<0.001$ and $p=0.009$, respectively). There was a significantly shorter distance from the SFA and PFA to the femur at the LT of 0.2mm (95% CI: 0.1-0.2) and 0.1mm (95% CI: 0.1-0.2), respectively, for each 1-year increase in age ($p<0.001$).
**Conclusion:** Responsible use of the MI-WP requires that the surgeon is aware of its differences from other wire passers; in particular, one of the jaws of one forceps-half extends forward by approximately 5mm during assembly. To minimise the risk of vessel injury, safe usage of the MI-WP should consider both the position of the extending forceps-jaw and the angle of insertion with respect to the surrounding vessels.

Keywords:
*cerclage wire, femoral fractures, complications, technique*

## INTRODUCTION

An increasingly ageing population has also resulted in an increase in the incidence of osteoporosis in our population. Osteoporosis is rapidly proving to be a major public health and economic burden. Cooper *et al.* projected that by 2050, there would be 3.2 million hip fractures in Asia[1]. The World Health Organization reported an increase in life expectancy of 5 years over the last 15 years[2], suggesting that the incidence of hip fractures is likely to increase. More recently, Cheung et al. projected that the number of hip fractures in Asia will increase by 2.28 times, from 1,124,060 in 2018 to 2,563,488 in 2050[3].

While neck of femur and intertrochanteric fractures form the majority of hip fragility fractures, complex fractures of the femoral shaft, including subtrochanteric fractures and periprosthetic fractures, are also encountered in daily practice. Reduction of these fracture patterns can be challenging, and cerclage wiring remains a popular reduction tool. Open wiring carries the risk of extensive soft tissue dissection near the fracture site, which may lead to non-union or delayed union. Percutaneous wiring carries the advantage of minimising the extent of soft tissue dissection, with previous studies demonstrating good outcomes and bony union when utilised in the treatment of periprosthetic4 and subtrochanteric fractures[5]. Percutaneous wiring may be performed using the conventional Beranger wire passer or the minimally invasive wire passer (MI-WP) [DepuySynthes®, Oberdorf, Switzerland]. Apivatthakakul et al. recently described a technical guide for safe use of percutaneous cerclage wiring around the femur using a conventional wire passer with relation to the adjacent neurovascular structures[4]. The MI-WP differs from the conventional wire passer in a few ways: it is inserted

Corresponding Author: Qing Hang Tan, Department of Orthopaedic Surgery, Changi General Hospital, 2 Simei St 3, Singapore 529889
Email: tanqinghang94@outlook.com

sequentially via two detachable forceps halves to form a full circle intra-operatively. This allows a reduced incision size, amount of tissue dislodgement, radiation exposure, and risk of vessel injury.

As the MI-WP is assembled and utilised in a manner that differs quite significantly from that of the conventional wire passer, we propose that the direction and angle in which these two detachable forceps halves are inserted and assembled at various levels of the femur should be considered distinct from that of the conventional wire passer to minimise the risk of vessel injury at these levels.

The study aimed to determine the spatial relationship of the superficial femoral artery (SFA) and profundal femoris artery (PFA) at the lower margin of the lesser trochanter (LT), midshaft of the femur (at a point halfway between the lesser trochanter and adductor tubercle) and the adductor tubercle (AT), and to propose a safe direction and angle of insertion of the MI-WP at these levels.

## MATERIALS AND METHODS

Ethics approval was obtained from the SingHealth Centralised Institutional Review Board (CIRB number 2017/2156). The computed tomographic angiograms (CTAs) of the lower limbs of consecutive patients over the age of 18 years old performed between January 2014 and December 2016 were obtained and reviewed. We excluded patients with a history of peripheral vascular disease, any history of trauma or previous surgery to a limb, pre-existing vascular malformation, or any lower limb deformities. The CT lower limb angiograms were performed on an Aquilion One 320-slice multidetector CT [Canon Medical Systems, Japan] following intravenous administration of 100ml of iodinated contrast at a rate of 4ml/s with a 30ml saline chaser. Scan coverage was from above the kidneys to the toes using acquisition parameters of 120 kVp, automated tube current modulation, collimation of 0.5mm x 80, and helical pitch of 65. Images in the axial plane were of 3mm thickness at 3mm interval and images in the coronal plane were 5mm thickness at 3mm intervals.

We measured the total length of the femur from the most inferior margin of the LT to the AT. We identified three levels within this region: the lower margin of the LT, midshaft of the femur (at a point halfway between the LT and AT), and the AT. These levels were identified as common sites of cerclage wiring in clinical practice: cerclage wiring is often used as a reduction tool at the lower margin of the LT during the fixation of subtrochanteric fractures, and at the midshaft during the fixation of periprosthetic hip fractures. At the adductor tubercle, cerclage wiring plays a role in assisting the reduction of distal femur fractures. The transepicondylar axis was used as a reference point for the version of the femur in the sagittal plane (Fig. 1).

On the axial CTA cuts, the shortest distance from the outer cortex of the femur to the SFA and the PFA at the inferior margin of the LT, femur midshaft and AT were recorded (Fig. 2, 3 and 4) To illustrate the spatial relationship of the SFA and PFA to the femur, we used a clockface orientation such that the most medial aspect of the right femur shaft in the axial plane from a “worm’s eye view” corresponds to the 3’oclock position (90°) and the posterior aspect of the femur shaft corresponds to the 6’oclock position (180°) (Fig. 5).

The linear mixed model was used to analyse differences in distance and the position of the vessels according to gender and age. Statistical analysis was performed with SPSS statistical software, version 19.0 [IBM Corp., Armonk, NY].

## RESULTS

A total of 101 limbs from 78 unique patients were included in the study. There were 54 left-sided and 47 right-sided limbs. The mean age was 54.3 ± 19.6 years. A total of 56 of these 78 patients were male. The mean distance from the LT to the AT was 306.7mm (95% CI: 302.1-311.3). The mean distances of the SFA to the femur at the inferior margin of the LT, femur midshaft, and AT were 39.2mm (95% CI: 37.8-40.6), 28.7mm (95% CI: 27.5-29.8), and 11.8mm (95% CI: 11.1-12.6), respectively. The mean distances of the PFA to the femur at the inferior margin of the LT and femur midshaft were 24.3mm (c) and 3.4mm (95% CI: 3.1-3.7), respectively.

The mean degree of the SFA with respect to the femur at the inferior margin of the LT, femur midshaft and AT were 56.3° (95% CI: 54.3 – 58.3, approximately 2’oclock in the right femur and 10’o clock in the left), 108.9° (95% CI: 104.4 – 113.3, approximately halfway between the 3 and 4’o clock position in the right femur and halfway between the 8 and 9’oclock position in the left) and 182.8° (95% CI: 180.7 – 184.9, approximately at the 6’o clock position in both the right and left femurs), respectively.

The mean degree of the PFA with respect to the femur at the inferior margin of the LT and femur midshaft were 59.1° (95% CI: 58.0 – 60.2, approximately at the 2’o clock position in the right femur and the 10’o clock position in the left) and 177.6° (95% CI: 175.2 – 180.1, approximately at the 6’o clock position in both the right and left femurs), respectively.

When comparing distances from the SFA to the femur at the three levels, univariate analysis showed that the mean distance of the SFA to the femur at the inferior margin of the LT was 6.8mm (95% CI: 4.1 – 9.5), further in males compared to females ($p<0.001$). The mean distance of the SFA to the femur at the femur midshaft was 6.8mm (95% CI: 4.6 – 9.0), further in males compared to females ($p<0.001$). Males also showed a significantly further distance from the PFA to the femur at the levels of the inferior margin of the LT and femur midshaft ($p<0.001$ and $p=0.009$, respectively) (Table I).

**Table I:** Univariate analysis comparing mean distance and position of the superficial femoral and profunda femoris arteries from the femur.

| | Male (n = 71 legs) | Female (n = 30 legs) | Beta Coefficient (95% CI) | p-value |
|---|---|---|---|---|
| **At the lesser trochanter** | | | | |
| Distance from SFA to femur (mm) | 41.2 (39.7-42.7) | 34.4 (32.2-36.7) | 6.78 (4.09 to 9.47) | < 0.001 |
| Distance from PFA to femur (mm) | 25.3 (24.1-26.5) | 22.0 (20.1-23.8) | 3.36 (1.16 to 5.56) | 0.003 |
| Degree of SFA (⊕) | 56.8 (54.4-59.3) | 55.0 (51.3-58.7) | 1.83 (-2.61 to 6.27) | 0.415 |
| Degree of PFA (⊕) | 59.4 (58.1-60.7) | 58.5 (56.5-60.5) | 0.87 (-1.53 to 3.27) | 0.476 |
| Distance from femur to SFA (mm) | 30.7 (29.5-31.9) | 23.9 (22.0-25.7) | 6.80 (4.61 to 9.01) | < 0.001 |
| Distance from femur to PFA (mm) | 3.7 (3.3-4.0) | 2.8 (2.3-3.4) | 0.84 (0.21 to 1.47) | 0.009 |
| Degree of SFA (⊕) | 107.1 (101.8-112.5) | 113.0 (104.8-121.2) | -5.89 (-15.68 to 3.91) | 0.236 |
| Degree of PFA (⊕) | 177.9 (175.0-180.8) | 177.0 (172.5-181.5) | 0.89 (-4.46 to 6.23) | 0.743 |
| **At the adductor tubercle** | | | | |
| Distance from SFA to femur (mm) | 11.6 (10.7-12.5) | 12.3 (11.0-13.7) | -0.74 (-2.39 to 0.90) | 0.373 |
| Degree of SFA (⊕) | 182.7 (180.3-185.2) | 183.0 (179.2-186.8) | -0.25 (-4.83 to 4.33) | 0.913 |

Reference category: Female
CI: confidence interval, SFA: superficial femoral artery, PFA: profundal femoris artery

**Table II:** Multivariate regression analysis comparing the mean distance and position of the superficial femoral and profunda femoris arteries from the femur.

| | Gender | Age | | |
|---|---|---|---|---|
| | B (95% CI) | p-value | B (95% CI) | p-value |
| **At the lesser trochanter** | | | | |
| Distance from SFA to femur (mm) | 5.1 (2.5 to 7.6) | < 0.001 | -0.2 (-0.2 to -0.1) | < 0.001 |
| Distance from PFA to femur (mm) | 2.0 (-0.1 to 4.1) | 0.061 | -0.1 (-0.2 to -0.1) | < 0.001 |
| Degree of SFA (⊕) | 0.6 (-4.0 to 5.1) | 0.806 | -0.1 (-0.2 to 0.0) | 0.051 |
| Degree of PFA (⊕) | 0.7 (-1.8 to 3.2) | 0.580 | -0.0 (-0.1 to 0.1) | 0.642 |
| **At the femur midshaft** | | | | |
| Distance from femur to SFA (mm) | 5.8 (3.6 to 8.0) | < 0.001 | -0.1 (-0.1 to -0.0) | 0.001 |
| Distance from femur to PFA (mm) | 0.8 (0.2 to 1.5) | 0.015 | -0.0 (-0.0 to 0.0) | 0.847 |
| Degree of SFA (⊕) | -0.3 (-9.8 to 9.1) | 0.945 | 0.48 (0.3 to 0.7) | < 0.001 |
| Degree of PFA at (⊕) | 1.0 (-4.6 to 6.6) | 0.732 | 0.0 (-0.1 to 0.1) | 0.917 |
| **At the adductor tubercle** | | | | |
| Distance from SFA to femur (mm) | 0.1 (-1.6 to 1.7) | 0.962 | 0.1 (0.0 to 0.1) | 0.001 |
| Degree of SFA (⊕) | -0.1(-4.9 to 4.7) | 0.980 | 0.0 (-0.1 to 0.1) | 0.774 |

Reference category: Female
CI: confidence interval, SFA: superficial femoral artery, PFA: profundal femoris artery

Multivariate regression analysis was performed to study the differences in the position and distance from the femur to the SFA and PFA based on gender and age (Table II). There was a 5.1 (95% CI 2.5 – 7.6) mm increase in distance from SFA to femur at the inferior margin of the LT and a 5.8 (95% CI 3.6 – 8.0) mm increase in distance from the SFA to the femur at the femur midshaft for a male compared to a female ($p<0.001$). There was a significantly shorter distance from the SFA and PFA to the femur at the level of the inferior margin of the LT of 0.2mm (95% CI: 0.1 – 0.2) and 0.1mm (95% CI: 0.1 – 0.2), respectively, for each 1-year increase in age ($p<0.001$ and $p<0.001$, respectively). There was also a significantly shorter distance from the SFA to the femur at the femur midshaft of 0.1mm (95% CI 0.0 – 0.1) for each 1-year increase in age ($p=0.001$).

## DISCUSSION

Given its versatility, cerclage wiring should remain in the armamentarium of the orthopaedic surgeon. It may be used as a temporary reduction tool or as a long-term implant during the surgical management of fractures. In the femur, the cerclage wire may be used prophylactically to prevent fractures, such as when broaching or inserting cementless implants. It may also be used to treat inadvertent fractures sustained intra-operatively and to facilitate reduction before intramedullary cannulation with a guidewire during cephalomedullary nailing of subtrochanteric and complex intertrochanteric fractures (Fig. 6).

The minimally invasive cerclage wire passer carries certain advantages over the conventional wire passer (Fig. 7). The latter consists of a cannulated half-circle with a handle. This half-circle is guided around the bone, and the cerclage wire

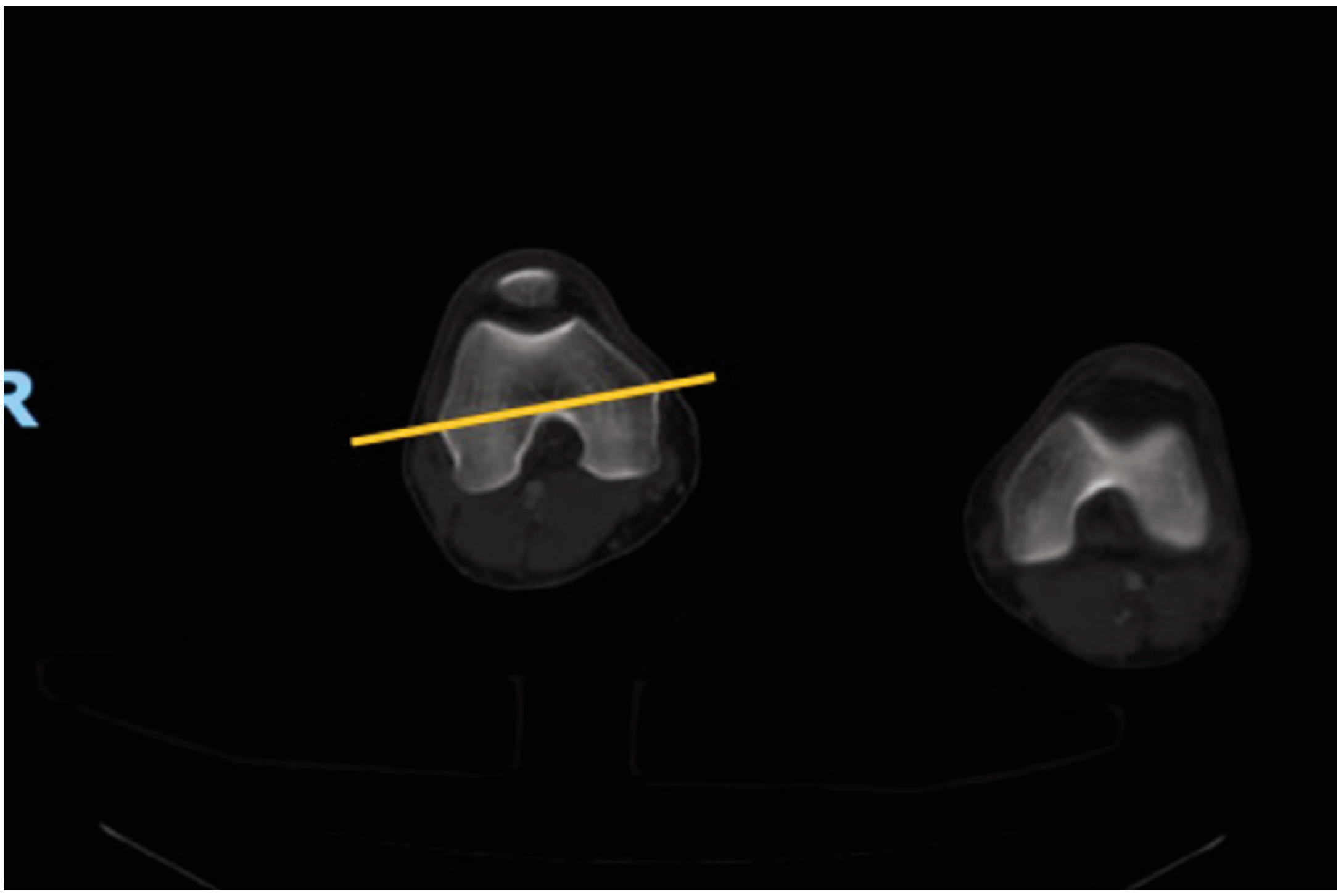


**Fig. 1:** Axial cuts showing the transepicondylar axis of the right distal femur.

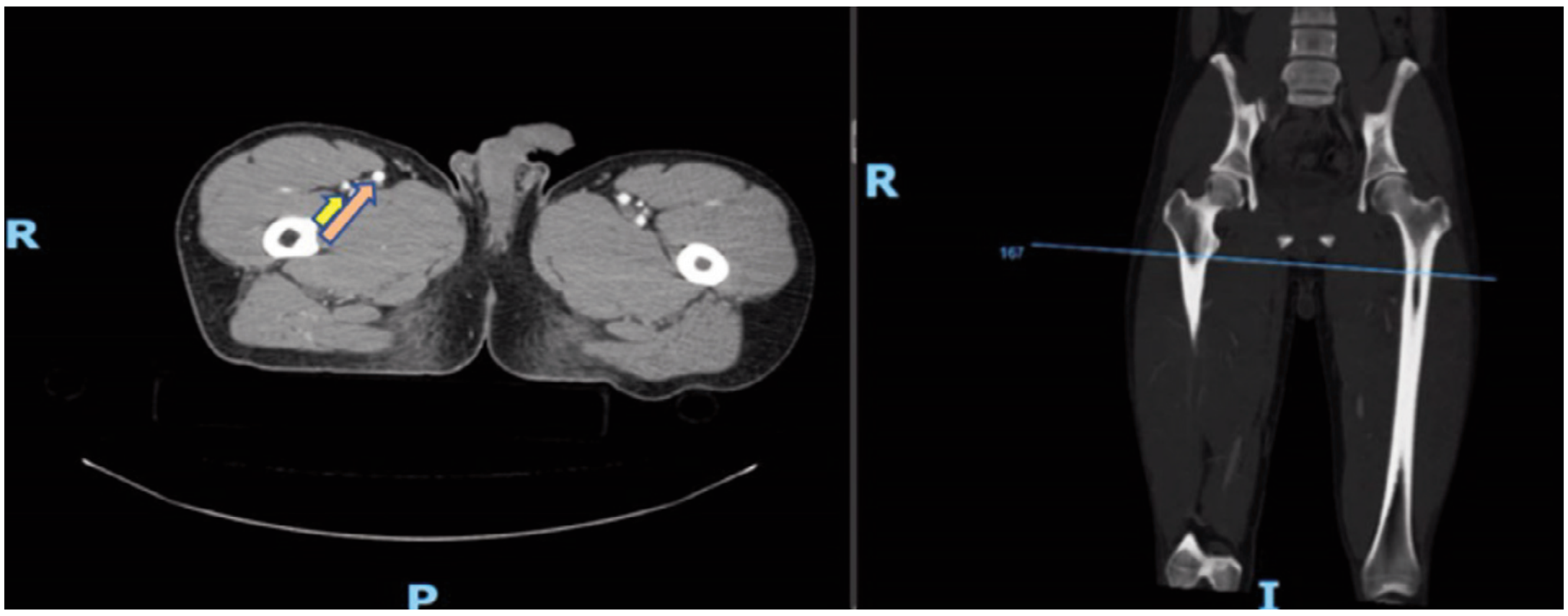


**Fig. 2:** Axial and coronal CT (computed tomography) cuts showing how the shortest distance from the outer cortex of the femur at the inferior margin of the lesser trochanter to the superficial femoral and profundal femoris artery is measured (yellow arrow: distance form femur to profundal femoris artery, red arrow: distance from femur to superficial femoral artery).

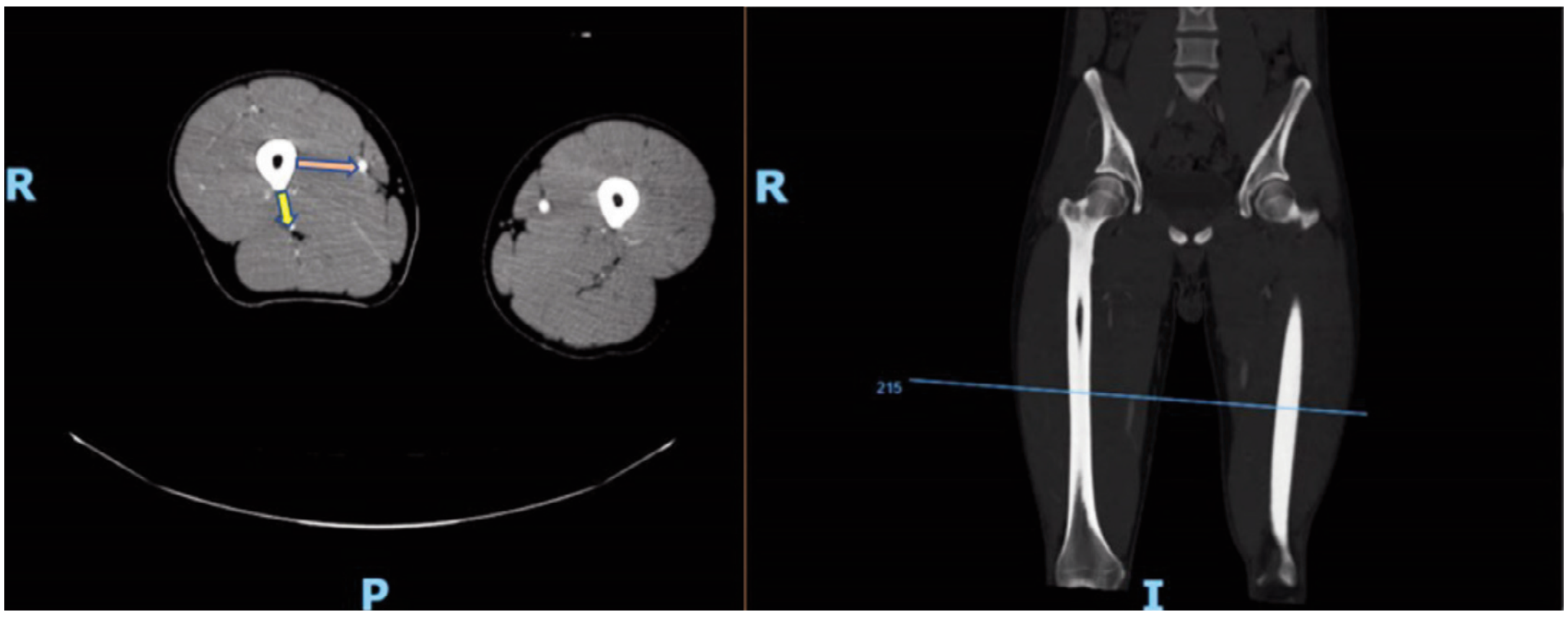


**Fig. 3:** A: Axial and coronal CT (computed tomography) cuts showing how the shortest distance from the outer cortex of the femur at the midshaft of the femur to the superficial femoral and profundal femoris artery is measured (yellow arrow: distance form femur to profundal femoris artery, red arrow: distance from femur to superficial femoral artery).

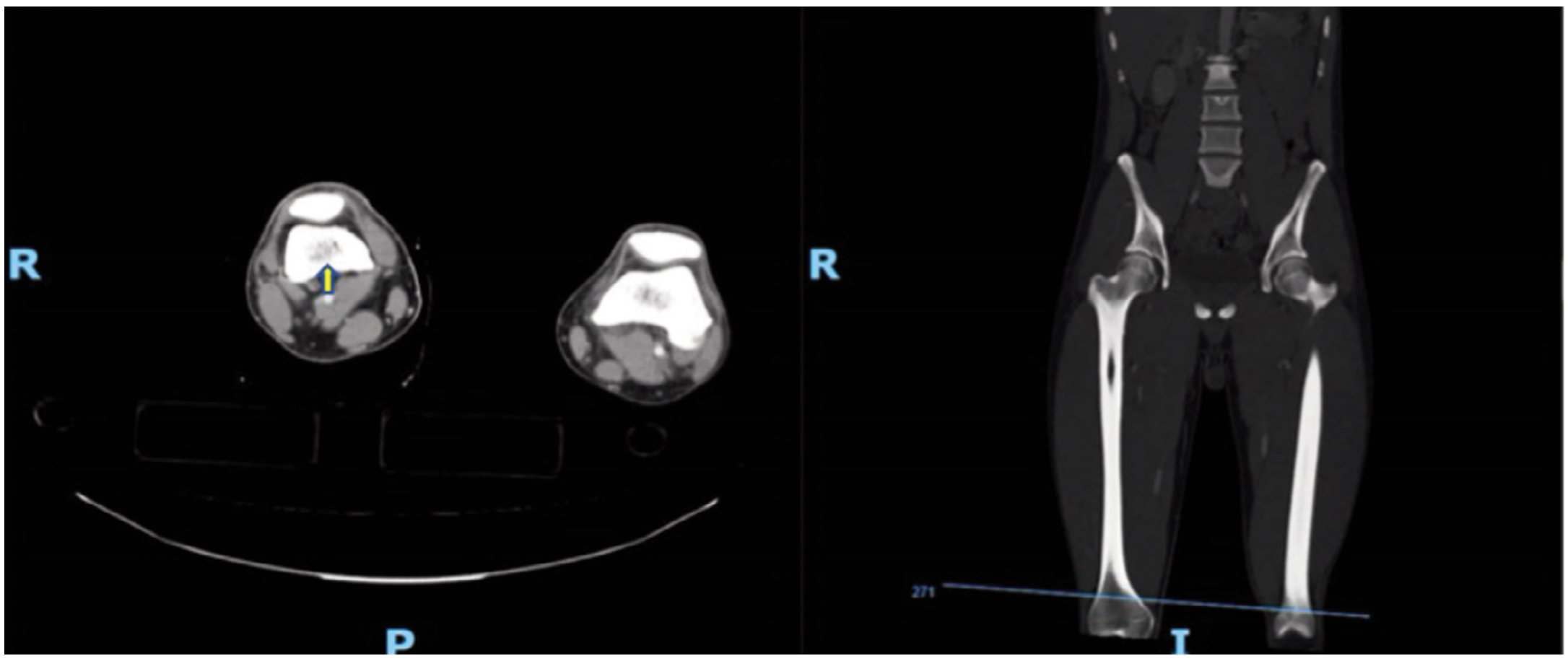


**Fig. 4:** Axial and coronal CT (computed tomography) cuts showing how the shortest distance from the outer cortex of the femur at the level of the adductor tubercle to the superficial femoral and profundal femoris artery is measured (yellow arrow: distance form femur to profundal femoris artery, red arrow: distance from femur to superficial femoral artery).

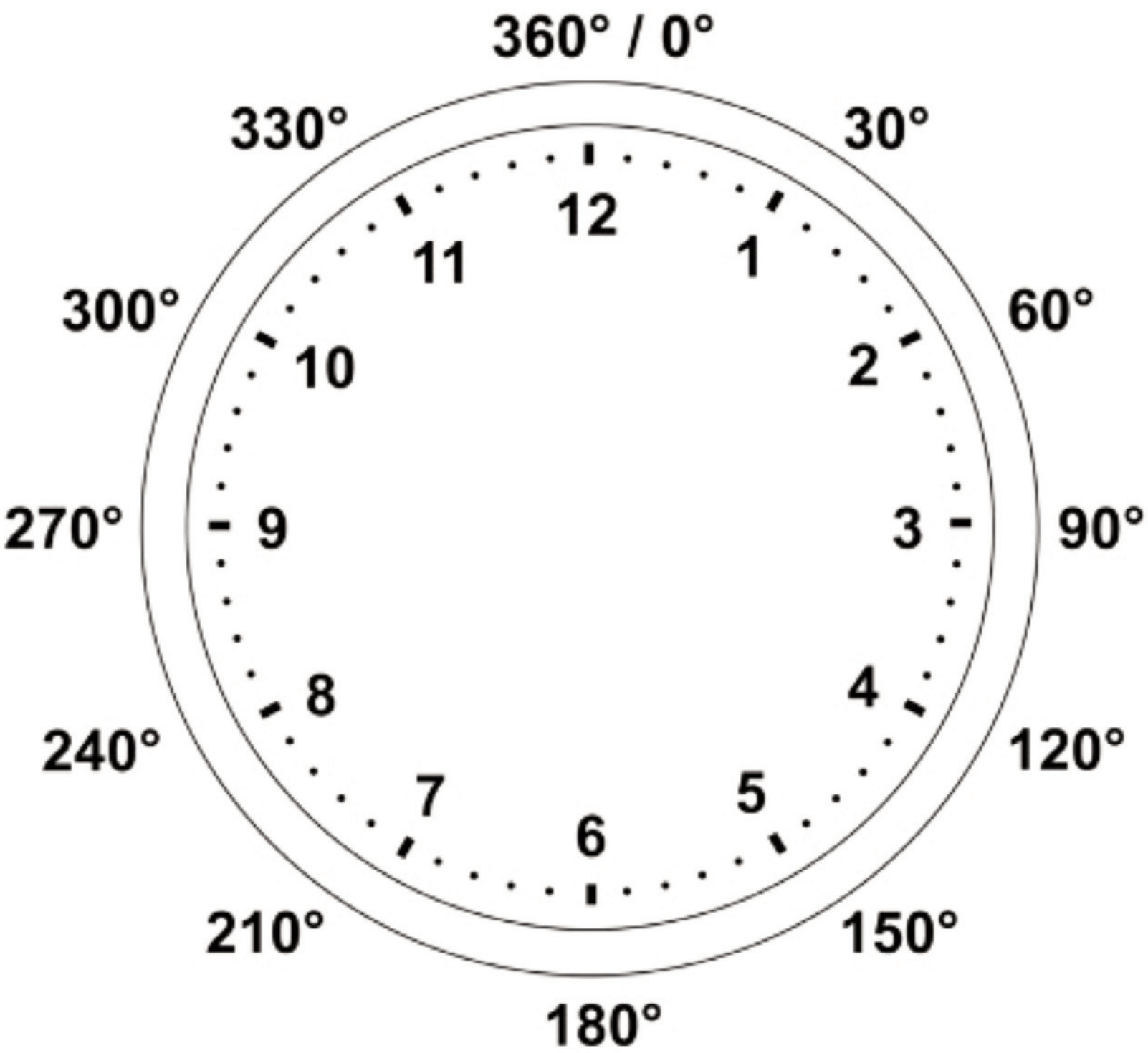


**Fig. 5:** Clock orientation (using the "worm's eye view" of the right femur as a reference) such that the most medial aspect of the right femur shaft in the axial plane corresponds to the 3'oclock position (90°).

is passed through. The cerclage wire is then retrieved from the other end of the passer; this technique, however, requires extensive tissue dislodgment in order to facilitate retrieval of the wire end, as shown by Perren *et al*. The MI-WP consists of two cannulated and detachable forceps-halves which connect in the middle to form a full circle around the bone, allowing the cerclage wire to be passed with minimal tissue dislodgment[7]. Its assembly involves the notch of the upper forceps sliding into the corresponding part of the lower forceps when connecting the device. This will result in the jaw of one forceps-half extending forward by approximately 5mm (Fig. 8). The MI-WP also allows for a smaller skin incision, reduced radiation exposure, and reduced risk of vessel injury compared to the conventional wire passer[7,8].

Despite the advantages of using the MI-WP, complications arising from its use have been reported. These include a 'Gigli saw effect' of the wire repeatedly sliding on the bone,

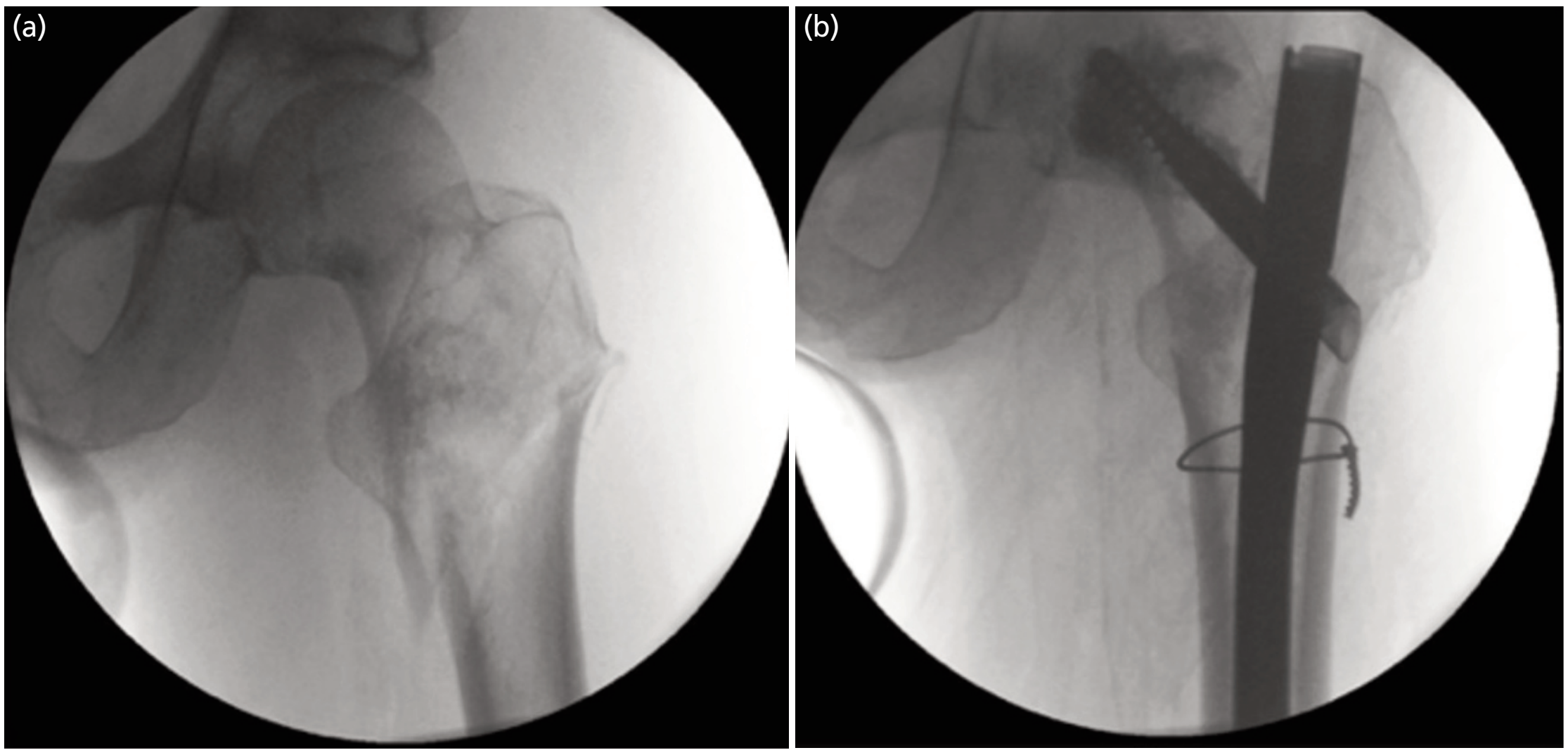


**Fig. 6:** (a) Intra-operative fluoroscopy images of a comminuted left subtrochanteric fracture. (b) Intra-operative fluoroscopy imaging showing application of a cerclage wire to facilitate reduction following intramedullary nailing of the subtrochanteric fracture.
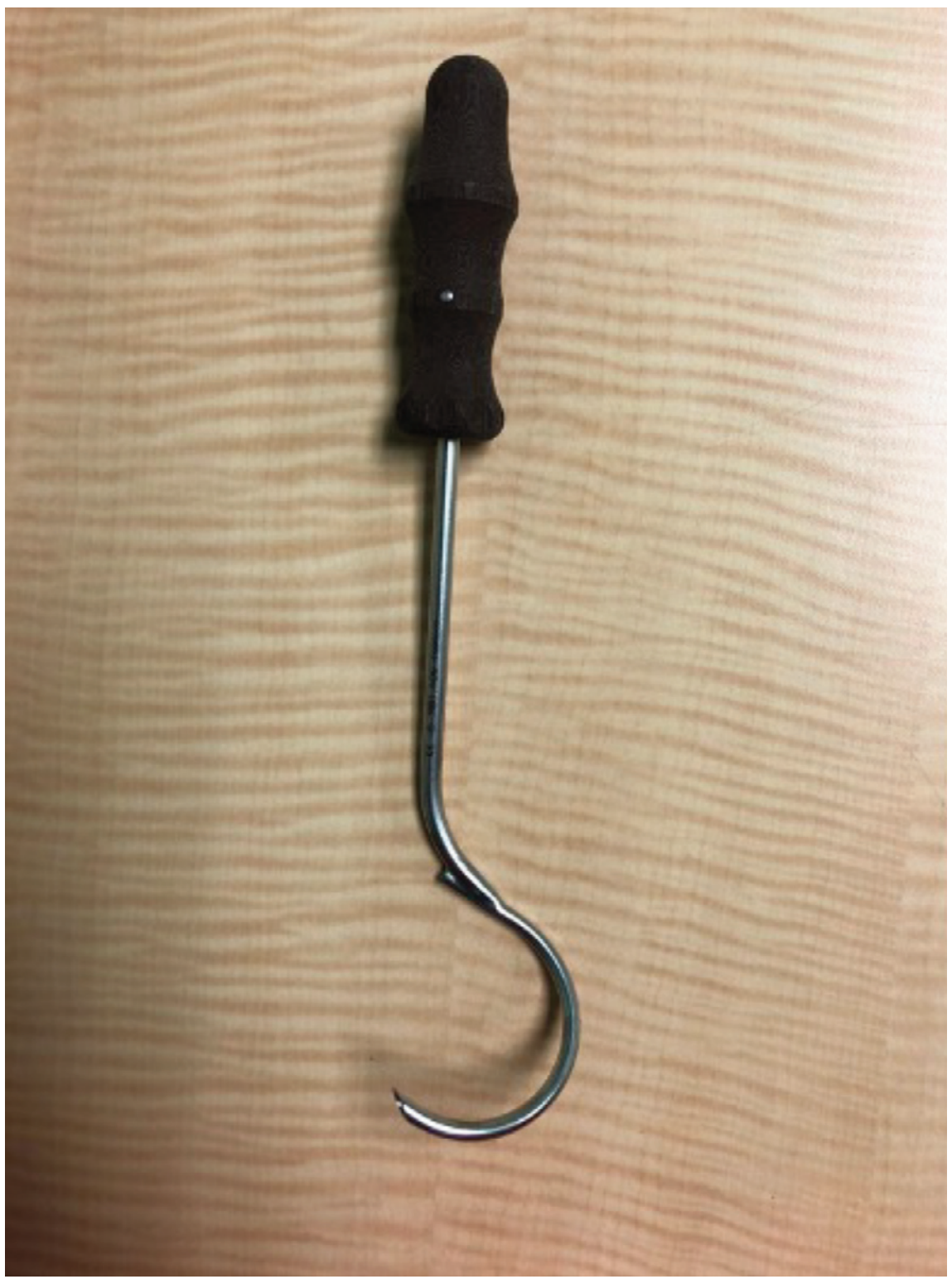
**Fig. 7:** Conventional wire passer.

potentially leading to damage to the periosteal blood supply[7] and the rare migration of broken wires from the patella and shoulder girdle to the heart[9,10]. Won *et al* reported on a case of an elderly patient with a femoral shaft fracture who underwent intramedullary nailing and cerclage wiring augmentation with a MI-WP[11]. The proximal cable was found to have caught the SFA, partially penetrating it. Despite removal and repair of the artery, the patient eventually required a below-knee amputation due to limb ischemia. Mehta *et al* also reported on a case of the cerclage wire placed at the midshaft of the femur, tethering the fascia adjacent to the femoral artery, indirectly leading to arterial occlusion[12]. Yang *et al* examined the position of the SFA in 59 patients in three positions commonly used in intramedullary nailing of the proximal femur using colour flow duplex scanning and found that positioning the patient with the perineal post against the medial thigh during nailing could inevitably move the SFA closer towards the femur.

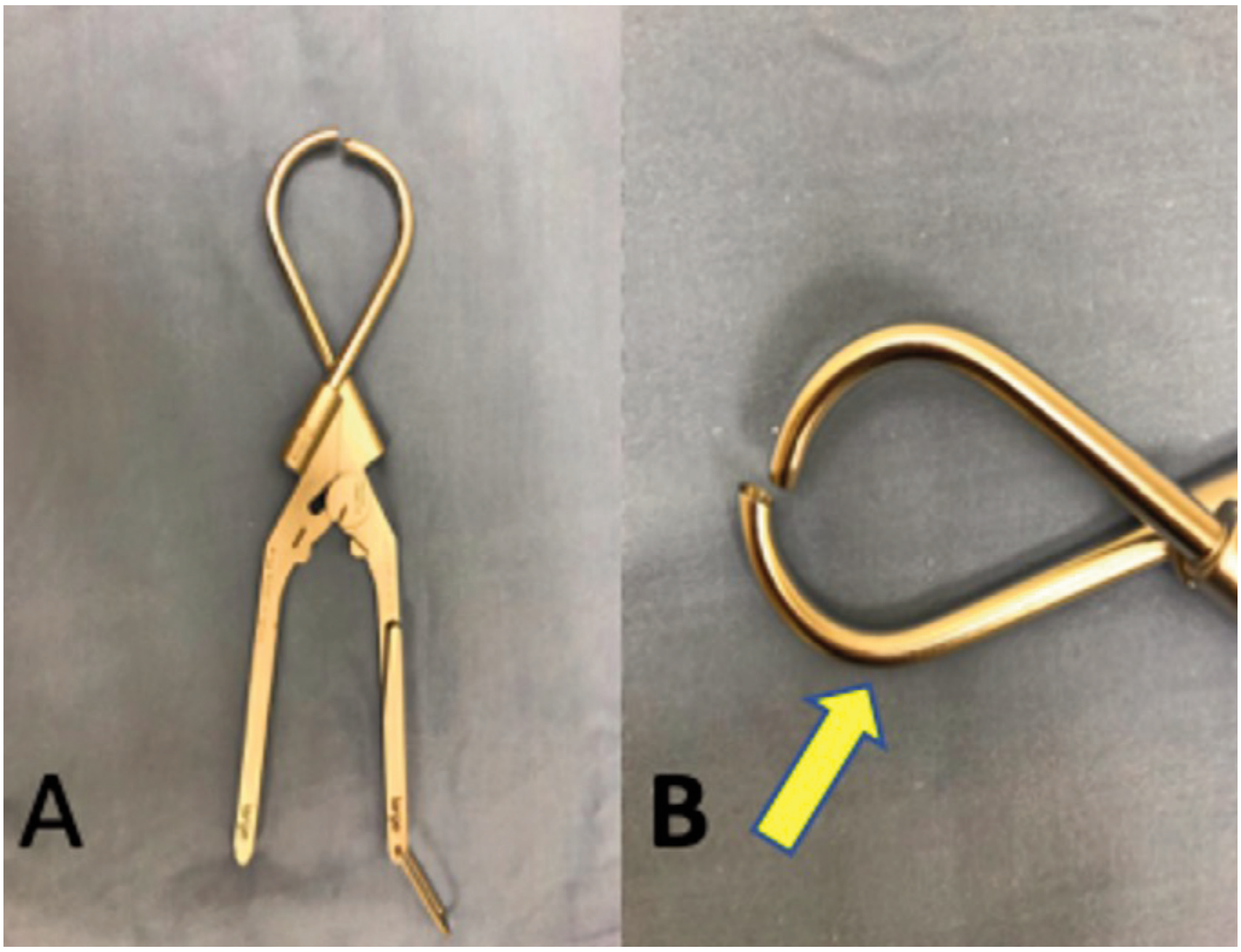


**Fig. 8:** (a) Minimally invasive wire passer with 2 detachable forceps halves. (b) Jaw of one forceps half (yellow arrow = F1) protruding forward 5mm during assembly.

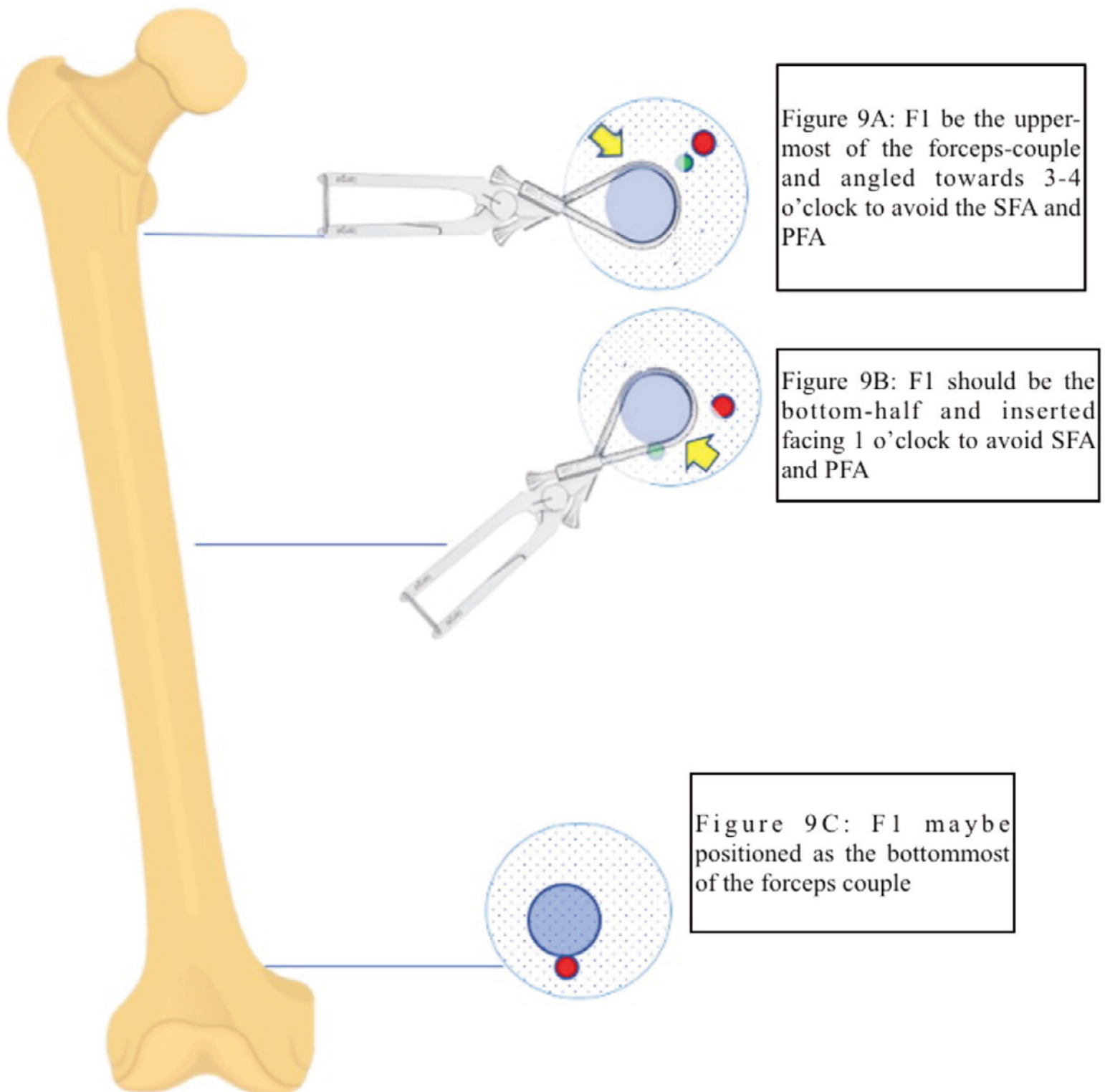


**Fig. 9:** (a) F1 be the upper-most of the forceps-couple, and angled towards 3 – 4'oclock to avoid the SFA and PFA of right femur. (b) F1 should be the bottom half and inserted facing 1 o'clock to avoid the SFA and PFA of right femur. (c) F1 may be positioned as the bottommost of the forceps couple. (●: superficial femoral artery (SFA) , ● : profunda femoris artery (PFA) , ⇗ = F1 : jaw of the forcep half that protrudes forward by 5mm during assembly of the minimally invasive wire passer).

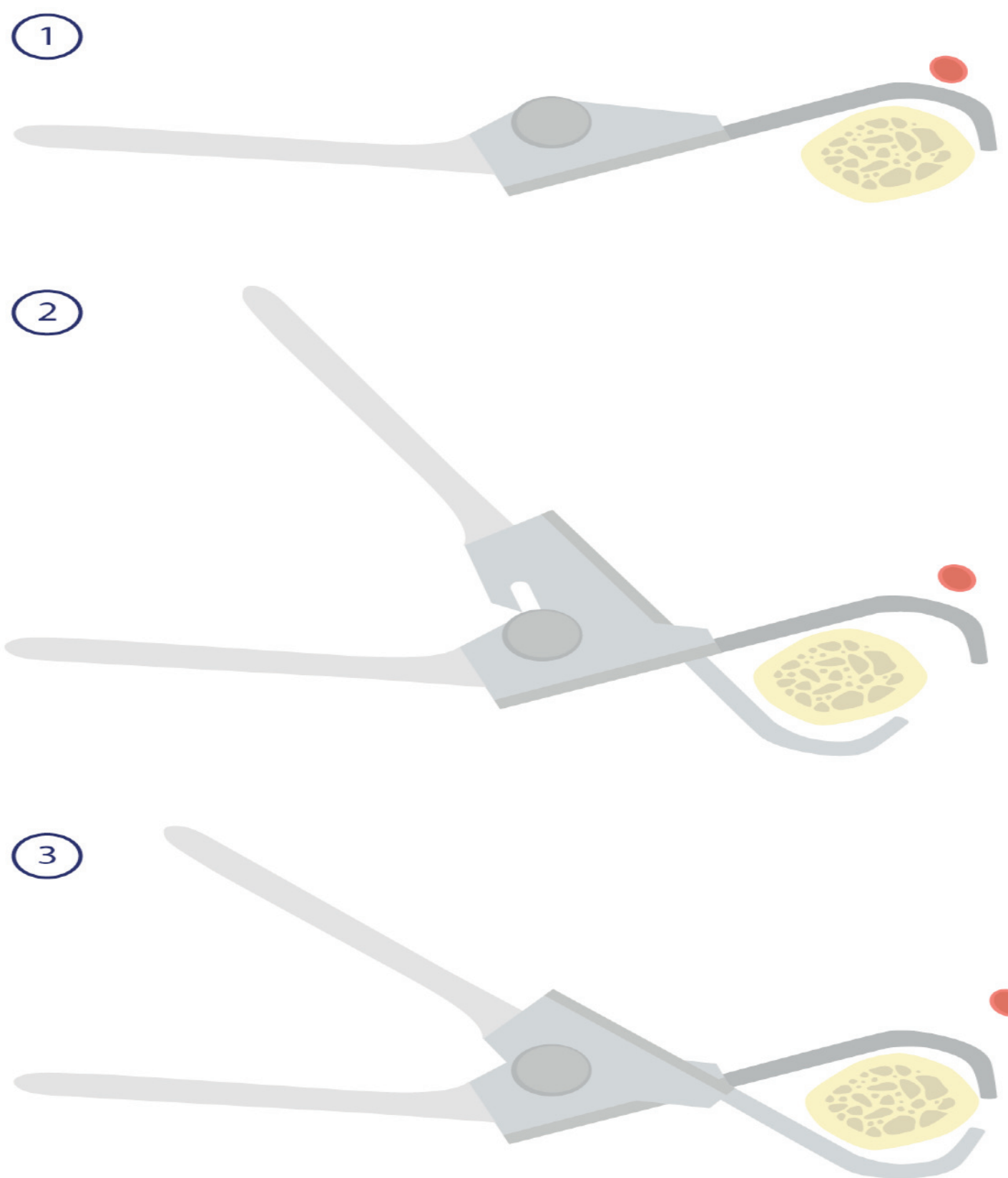


**Fig. 10:** (a) The F1 forceps couple should be inserted first, and the tip should be passed beyond the point of the vessel. (b) The second jaw of the forceps couple would then be inserted, and during the assembly of the forceps, the F1 jaw would displace forward by 5mm. As the tip is beyond the position of the vessel, this movement would not entrap the vessel within the wire passer assembly. (c) The fully assembled wire passer.

Positioning the hip in a neutral manner rather than an adducted position provides a wider zone of safety between the femoral shaft and the femoral artery[13]. Another anatomical consideration is that in the midshaft to distal third of the thigh, the SFA becomes more tethered in adductor hiatus where it becomes the popliteal artery. This may lead to a smaller effective working space during the placement of the cerclage wiring, and this space decreases with fracture displacement. While these complications are uncommon, they can have devastating effects on patient outcome, and surgeons must make every effort to minimise the risk of such complications.

We propose that, as the MI-WP differs significantly from the conventional wire passer in its design and use, the direction in which the MI-WP is inserted should be considered distinct from that of the conventional wire passer to minimise vessel injury.

At the inferior margin of the LT, the mean position of the SFA and PFA were 56.3° and 59.1°, respectively, both of which can be approximated to be the 2 o'clock position in the right femur and 10 o'clock position in the left. Hence, we propose that F1 be the upper-most of the forceps couple, and angled towards 3 – 4 o'clock in the right femur, and towards the 8 – 9 o'clock position in the left femur to avoid injuring the SFA and PFA (Fig. 9a).

At the midshaft of the femur, the mean position of the SFA was 108.9°, which can be approximated to be halfway between the 3 and 4 o'clock position in the right femur and halfway between the 8 and 9 o'clock position in the left. The mean position of the PFA was 177.6°, which can be approximated to be at the 6 o'clock position in both the right and left femurs. Hence, we propose that F1 should be the bottom half of the forceps couple and inserted facing 1 o'clock in the right femur and towards the 11 o'clock position in the left femur to avoid the vessels (Fig. 9b).

At the adductor tubercle, the mean position of the SFA was 182.8°, which can be approximated to be at the 6 o'clock position in both the right and left femurs. Hence, we propose that F1 may be positioned either as the bottommost of the forceps couple during its insertion into both the right and left femurs (Fig. 9c).

This study also showed that at the level of the inferior margin of the LT and femur midshaft, there was a significant increase in distance of at least 5mm from the SFA to the femur for a male compared to a female. While 5mm may be a relatively small distance, during assembly of the MI-WP, the jaw of one forceps-half does extend forward by approximately 5mm and may lead to SFA injury, particularly in a lean female. Furthermore, this distance may be reduced during positioning against the peroneal post when attempting to reduce the fracture for nailing. Also, in the mid to distal third of the thigh, the SFA is likely to be more tethered as it enters the adductor hiatus. Our study also showed a significantly shorter distance from the SFA and PFA to the femur at the level of the inferior margin of the LT of 0.2mm and 0.1mm, respectively, for each 1-year increase in age, and a significantly shorter distance from the SFA to the femur at the femur midshaft of 0.1mm for each 1-year increase in age. While these distances are relatively small, they can be significant in an older patient with a femoral fracture. As such, we emphasise the importance of recognising that safe usage of the MI-WP requires both a consideration of the position of the extending forceps-jaw and the angle at which it is inserted based on the level of the fracture in the femur.

There are studies detailing safe zones and techniques for percutaneous cerclage wire passing[6,14], but to our knowledge, this is the first study appreciating the importance of the angle at which the MI-WP is inserted and the order in which the forcep-halves of the MI-WP are assembled in order to minimise the risk of arterial injury. We also observed that age and patient gender are related to the proximity of the femoral vessels to the femur. This may be related to sarcopenia with increasing age[15]. In addition, the MI-WP is available in two sizes: a smaller one with a diameter of 46mm and a larger one with a diameter of 60mm. As such, when selecting the appropriately sized wire passer to use, it is important to take into account the age and gender of the patient.

There were some limitations in our study. This was a retrospective analysis of CTAs instead of a cadaveric study. We did not include body mass index measurements in our analysis, which may impact the vessel distance to the femur. We also performed our study based on the CTAs of patients with intact femurs, whereas the data we obtained would be applied to patients with fractured femurs, who will more likely have distorted tissue planes and soft tissue swelling.

## CONCLUSION

The surgeon should be especially cautious in patients who are female and elderly when using the MI-WP for cerclage wiring near the LT and the femoral midshaft, as the vessels are in closer vicinity to the femur. Responsible use of the MI-WP also requires that the surgeon is aware of its differences from other wire passers; in particular, one of the jaws of one forceps-half extends forward by approximately 5mm during its assembly. We propose that to minimise the risk of vessel injury, safe usage of the MI-WP should consider both the position of the extending forceps-jaw and the angle at which it is inserted.

## ACKNOWLEDGEMENTS

The authors would like to thank Dr Woo Chin Yee for her help in designing Figure 5 during the preparation of this manuscript as well as Dr Bing Qian for his help in designing Figure 10 during the revision of this manuscript.

## CONFLICT OF INTEREST

The authors declare no potential conflict of interest.

## REFERENCES


1. Cooper C, Campion G, Melton LJ 3rd. Hip fractures in the elderly: a world-wide projection. *Osteoporos Int.* 1992; 2(6): 285-9. doi: 10.1007/BF01623184
2. Kim J, Lee E, Kim S, Lee TJ. Economic Burden of Osteoporotic Fracture of the Elderly in South Korea: A National Survey. *Value Health Reg Issues.* 2016; 9: 36-41. doi: 10.1016/j.vhri.2015.09.007
3. Cheung CL, Ang SB, Chadha M, Chow ES, Chung YS, Hew FL, *et al.* An updated hip fracture projection in Asia: The Asian Federation of Osteoporosis Societies study. *Osteoporos Sarcopenia.* 2018; 4(1): 16-21. doi: 10.1016/j.afos.2018.03.003
4. Apivatthakakul T, Phornphutkul C, Bunmaprasert T, Sananpanich K, Fernandez Dell'Oca A. Percutaneous cerclage wiring and minimally invasive plate osteosynthesis (MIPO): a percutaneous reduction technique in the treatment of Vancouver type B1 periprosthetic femoral shaft fractures. *Arch Orthop Trauma Surg.* 2012; 132(6): 813-22. doi: 10.1007/s00402-012-1489-4
5. Kim JW, Park KC, Oh JK, Oh CW, Yoon YC, Chang HW. Percutaneous cerclage wiring followed by intramedullary nailing for subtrochanteric femoral fractures: a technical note with clinical results. *Arch Orthop Trauma Surg.* 2014; 134(9): 1227-35. doi: 10.1007/s00402-014-2023-7
6. Apivatthakakul T, Siripipattanamongkol P, Oh CW, Sananpanich K, Phornphutkul C. Safe zones and a technical guide for cerclage wiring of the femur: a computed topographic angiogram (CTA) study. *Arch Orthop Trauma Surg.* 2018; 138(1): 43-50. doi: 10.1007/s00402-017-2804-x
7. Perren SM, Fernandez Dell'Oca A, Lenz M, Windolf M. Cerclage, evolution and potential of a Cinderella technology. An overview with reference to periprosthetic fractures. *Acta Chir Orthop Traumatol Cech.* 2011; 78(3): 190-9.
8. Angelini A, Battiato C. Past and present of the use of cerclage wires in orthopedics. *Eur J Orthop Surg Traumatol.* 2015; 25(4): 623-35. doi: 10.1007/s00590-014-1520-2
9. Biddau F, Fioriti M, Benelli G. Migration of a broken cerclage wire from the patella into the heart. A case report. *J Bone Joint Surg Am.* 2006; 88(9): 2057-9. doi: 10.2106/JBJS.E.00968
10. Wirth MA, Lakoski SG, Rockwood CA Jr. Migration of broken cerclage wire from the shoulder girdle into the heart: a case report. *J Shoulder Elbow Surg.* 2000; 9(6): 543-4. doi: 10.1067/mse.2000.109413. Erratum in: *J Shoulder Elbow Surg.* 2001; 10(4): 384.
11. Won Y, Yang KH, Kim KK, Weaver MJ, Allen EM. Amputated limb by cerclage wire of femoral diaphyseal fracture: a case report. *Arch Orthop Trauma Surg.* 2016; 136(12): 1691-4. doi: 10.1007/s00402-016-2580-z
12. Mehta V, Finn HA. Femoral artery and vein injury after cerclage wiring of the femur: a case report. *J Arthroplasty.* 2005; 20(6): 811-4. doi: 10.1016/j.arth.2004.12.050
13. Yang KH, Yoon CS, Park HW, Won JH, Park SJ. Position of the superficial femoral artery in closed hip nailing. *Arch Orthop Trauma Surg.* 2004; 124(3): 169-72. doi: 10.1007/s00402-003-0618-5
14. Apivatthakakul T, Phornphutkul C. Percutaneous cerclage wiring for reduction of periprosthetic and difficult femoral fractures. A technical note. *Injury.* 2012; 43(6): 966-71. doi: 10.1016/j.injury.2011.11.007
15. Kuk JL, Saunders TJ, Davidson LE, Ross R. Age-related changes in total and regional fat distribution. *Ageing Res Rev.* 2009; 8(4): 339-48. doi: 10.1016/j.arr.2009.06.001


**Cite this article:**
Ng SWL, Tan QH, Chong LR, Kam CJW, Yeo AKS. Anatomical Considerations in the Utilisation of Minimally Invasive Cerclage Wiring for Femoral Fracture Fixation. *Malays Orthop J.* 2026; 20(2): xx-xx. doi: