doi: https://doi.org/10.5704/MOJ.2611.007

The Impact of the Learning Curve on Surgical Performance Focused on Achieving Medial Support in Complex Proximal Humeral Fracture: ORIF using a Locking Plate

Lim TK[1], MD, **Koh KH**[2], MD, **Lee TH**[3], MD, **Shon MS**[3], MD

[1]Department of Orthopaedic Surgery, Nowon Eulji University Hospital, Seoul, South Korea
[2]Department of Orthopaedic Surgery, Asan Medical Center, Seoul, South Korea
[3]Department of Orthopaedic Surgery, National Medical Center, Seoul, South Korea



This is an open-access article distributed under the terms of the Creative Commons Attribution License, which permits unrestricted use, distribution, and reproduction in any medium, provided the original work is properly cited

Date of submission: 25th December 2024
Date of acceptance: 26th September 2025

ABSTRACT

Introduction: This study aimed to evaluate whether the surgical performance, focused on achieving medial support, improved during the learning curve periods of novice surgeons performing ORIF of complex proximal humeral fracture (PHF) using a locking plate.

Materials and methods: This retrospective study was conducted on 62 patients who underwent ORIF for complex PHFs by 3 shoulder specialists at the beginning of their practices. Patients were divided into two groups based on fixation during the 1st year of practice (Group A) and the subsequent year (Group B). The primary outcome assessed was the achievement of medial support in the proximal humerus, and secondary outcomes included patient demographics, clinical outcomes, radiological outcomes, technical errors, and complications.

Results: There were no statistically significant differences in demographic data, fracture distribution, initial medial comminution, clinical outcome, and post-operative stiffness at the final follow-up. Interestingly, we found statistically significant increases with regard to medial support (p=0.027) and adequate plate positioning (p=0.008) in Group B compared to Group A.

Conclusion: The study highlights that the learning curve for novice surgeons performing ORIF for PHFs demonstrated significant improvement over time in achieving medial support, though clinical outcomes were comparable between early and later cases. Emphasising this technical goal may help accelerate skill acquisition and enhance fixation quality in complex PHFs using locking plates.

Keywords:
proximal humeral fracture, open reduction and internal fixation, locked plate, medial support, learning curve

INTRODUCTION

Although the optimal treatment for proximal humerus fractures has not yet been established, open reduction and internal fixation (ORIF) using a locking plate for displaced fractures is currently recommended as a viable option[1]. Biomechanically, the fixed-angle locked-plate system maintains angular stability under load,[2,3] and can resist physiologic load in osteoporotic bones[4,5]. Many clinical studies support this biomechanical superiority through successful bone healing and the restoration of shoulder functions[6,7].

However, the surgical outcomes are still unpredictable. Moreover, complications were somewhat common, while rates vary significantly, ranging from 24% to 36%[5,8,9]. Various complications have been reported so far, such as implant failure, loss of reduction, non-union or malunion of the fracture, plate impingement, and osteonecrosis of the humeral head. Several factors, such as bone quality, fracture patterns, the magnitude of the reduction, or technical errors, etc., affect the mechanical stability of fracture fixation and surgical outcome. The complexity of fracture geometry in the proximal humeral region and co-existing osteoporosis may preclude the achievement and maintenance of accurate reductions of displaced fragments. Plates placed too far cranially can lead to subacromial impingement; very short screws in the head fragment can cause secondary fragment

Corresponding Author: Minsoo Shon, Department of Orthopaedic Surgery, National Medical Center, 245 Eulji-ro, Jung District, Seoul, South Korea
Email: minsoo.shon@nmc.or.kr

displacement; very long screws can lead to perforation of an articular surface of the humeral head, and eventually painful limitations of motion and damage to the glenoid articular cartilage; extensile exposure of the fracture always places the humeral head at risk of avascular necrosis[8-10]. These various wide-ranging complication rates may also pertain to technical difficulties and a lack of reproducibility of the optimal fixations performed by different surgeons, centres, or techniques used.

Many orthopaedic surgeons believe that adequate reduction and biomechanical stability are far more important than the fracture patterns or initial displacements in terms of the likelihood of complications. Despite the biomechanically superior stability of the locking plate itself, it remains susceptible to varus collapse, especially in proximal humeral fracture with medial comminution and inadequate reduction of the medial column[11]. There is an emphasis on the importance of mechanical support of the medial column for fracture stability. Gardner *et al.* [12] suggested that achieving mechanical support of the inferior-medial region of the proximal humerus appears to be important for more stable support and better maintenance of fracture reduction. Thereafter, several studies have stated that medial calcar continuity is necessary for surgical reduction, and medial support with screw fixation significantly improved the stability of fracture fixation[13-15].

Although such procedures are technically demanding, they are more difficult than expected to perform by less experienced and beginner surgeons[16]. As learning curves exist in other orthopaedic procedures,[17,18] a technical improvement over the learning curve could result in good outcomes and lower complication rates for locking plate fixation for proximal humeral fracture. Therefore, the purpose of this study was to evaluate whether surgical performance, focused on achieving medial support, improved during the learning periods of young, beginner surgeons for ORIF of proximal humeral fracture, using a locking plate. We hypothesised that surgical performance, particularly in achieving medial support, would improve significantly after the first year of practice. In addition, we compared the rate of technical errors in radiographs, complications, and functional outcome between two periods of clinical practice.

MATERIALS AND METHODS

During the initial two years based on the time of clinical practice (from March 2011 to October 2014), we thoroughly reviewed medical records and radiographs of 76 patients who underwent surgical treatments for proximal humeral fractures performed by three fellowship-trained shoulder specialists in orthopaedic surgery, who had just started their own practices in three different institutions. Institutional review boards of each of the three different hospitals approved this study and the need to obtain informed patient consent was waived.

Inclusion criteria were as follows: (1) patients 18 years old and over; (2) patients presenting with an acute (< 3 weeks) 3-part or 4-part proximal humeral fracture, and displaced 2-part surgical neck fracture which was deemed unstable, such as with less than 50% contact between the shaft and the head fragment, varus or valgus displacement, or extensive metaphyseal comminution; (3) patients treated with an ORIF using a locking plate; (4) availability of adequate pre-operative and post-operative radiographs; (5) follow-up until confirmation of the union of the fracture or at least one year after surgery.

Exclusion criteria included the presence of isolated greater or lesser tuberosity fractures, open fractures, pathologic fractures, revision surgeries, previous history of surgery or morbidity around the ipsilateral shoulder, or evidence of neurovascular compromise from the initial trauma. Patients treated with ORIF using a locking plate fixation with fibular allograft augmentation were also excluded.

Detailed patient history, including age, sex, arm involved, T-score (average in L1-L4) in bone marrow density (BMD), days from injury to surgery, and surgical time (defined as the time from the skin incision to closure) were reviewed. Pre-operative plain radiographs and 3D computed tomography were analysed for fracture pattern (Neer's classification and AO/OTA classification)[19,20] and the presence of medial metaphyseal comminution. Patient demographics for all consecutive cases are described in Table I.

The goal of the surgical operations in this study was to acquire acceptable reduction and stability in a displaced or unstable fracture, and the surgical method was decided after comprehensive pre-operative evaluations. All patients were placed in a beach chair position under general anaesthesia.

All surgeons used the deltopectoral approach and identified the anterior terminal branch of the axillary nerve, while paying attention throughout the procedure to avoid iatrogenic nerve injury. Fracture identification was performed carefully with minimal periosteal stripping to avoid further damage to soft tissue attached to fracture fragments. The biceps tendon and the bicipital groove served as landmarks to identify and reduce the fragments. When required, an incisional opening of the rotator interval and partial release of the coracoacromial ligament were performed to promote mobilisation and improve visualisation. Traction sutures using non-absorbable suture materials were applied through the bone-to-tendon junction of the rotator cuff for manual reduction of the fragments of the tuberosities.

After identification of the fracture patterns with main fragments, reduction was performed using closed manipulation. Firstly, anatomical restoration of head fragments was achieved by reduction using traction sutures and temporary fixation using Kirschner wires or trans-osseous suturing. Then, a rotational (varus or valgus) deformity of the head was corrected using a blunt instrument or Kirschner wire as a 'joystick' under fluoroscopy guidance.

The locking plate [PHILOS; Proximal Humerus Interlocking System, DePuy Synthes, Oberdorf, Switzerland] was applied in a correct position, below the apex of the greater tuberosity, to prevent mechanical impingement, and placed 2 – 4mm posterior (lateral) to the bicipital groove. If the residual translation of the shaft under the head fragment remained, a conventional 3.5mm cortical screw was inserted bicortically into the most proximal of the distal diaphyseal screw holes into the humeral shaft, to function in a manner similar to the reduction screw. Finally, the remaining 3.5mm locking screws were inserted into distal diaphyseal screw holes, and the proximal head screw was placed such that the longest screws were located in the subchondral bone without perforation.

Particular attention was paid to anatomical reduction and good alignment of the medial cortex in fractures without medial comminution. In the case of a fracture with medial comminution, the surgeons attempted to achieve two or three inferomedial screw (a superiorly directed oblique locking screw placed into the inferomedial quadrant of the humeral head fragment) insertions, or the intended slight impaction of the humeral shaft onto the humeral head, or both, to restore stable medial support. In the case of a substantial defect in the metaphysis after reduction, allograft bone chips or bone substitutes were used to fill the defect in order to assist healing at the surgeon's discretion. If additional stability was required in case of porotic bone quality or combined comminution of the greater tuberosity fracture fragments, cuff augmentation using non-absorbable suture materials was performed, by passing through proximal suture holes in the plate.

Data collection was initiated after obtaining approval for this study from the Institutional Review Boards of each hospital. To analyse the impact of learning curves on surgical performance, all patients were divided into two groups, namely, the first one-year (Group A) and subsequent one-year (Group B), based on the time of clinical practice. In particular, we assessed whether medial support during ORIF for displaced proximal humeral fracture was achieved as a primary variable. In addition, we assessed the clinical and radiographic outcome, including technical errors, along with the occurrence of complications and revision surgeries as secondary variables.

For the evaluation of clinical results, the pain visual analogue scale (PVAS), subjective shoulder value (SSV), and American Shoulder and Elbow Surgeons (ASES) score, and data such as range of motion (ROM), were investigated. The concept of 'patient-defined stiffness' was used to evaluate ROM at the final follow-up. Acquiring sufficient ROM is important in the early stages, after the operation, for the treatment of displaced proximal humerus fracture, even though the use of full ROM may be unnecessary to perform a functional task. An investigation was made to assess the prevalence of patient-defined stiffness, considering that stiffness was subjectively defined by patients, which was clinically more relevant than a physical examination threshold system.

Additionally, an investigation was performed to identify the development of other complications since the initial operation. Plain radiographs were obtained immediately after the operation and at a mean of 14.84 ± 53.00 months, as a final follow-up. Standardised radiographs at each time point post-operatively were evaluated in the anteroposterior (AP), true glenohumeral joint AP, and lateral (scapular Y) views. Radiographs obtained immediately after the operation were analysed for fracture reduction and implant placement. The medial support is defined as an anatomical reduction and alignment of the medial column in cases where there is no medial comminution (Fig. 1a). In cases with medial comminution, it is defined as the insertion of two or three inferomedial screws or reduction with the intended slight impaction, or both (Fig. 1b). Additionally, we assessed the neck-shaft angle (Fig. 2) in the AP view of the plain radiograph. Varus malreduction of the fracture was defined as a neck-shaft angle less than 120° based on immediate post-operative radiographs, and varus collapse of the humeral head was defined as a neck-shaft angle less than 120° based on post-operative radiographs obtained during the follow-up period. Other technical errors, such as screw penetration through the articular surface of the humeral head and placement of the plate higher than the apex of the greater tuberosity, were evaluated by referring to the radiographs obtained immediately after the operation. We also assessed failure of reduction or mechanical failure, such as screw cutout or loosening, non-union, and avascular necrosis of the humeral head, through plain radiographs at the final follow-up. Independent observers, who did not perform any of the operations, reviewed all the plain radiographs.

A comparison was conducted to determine the presence of differences between the two groups with regard to the different variables. Continuous variables were compared using Student's t-test, and categorical data were compared using the chi-square test and Fisher's exact test. Statistical analyses were performed with the SPSS program version 18.0.0.0 [IBM Corp.] with a significance level of 0.05 for all analyses.

RESULTS

In total, 62 patients who met the inclusion criteria participated in this study, and demographic characteristics of all cases are summarised in Table I. There were 26 male and 36 female patients. The mean age at the time of injury was 64.6 years (range, 30-90). The mean time from the injury to surgery was 6.3 days (range, 1-20). The BMD of 32 patients was measured; the average value of the T-score was -2.79 ± 1.16. All fractures were classified according to Neer's classification: 35 patients presented with a two-part fracture, 19 presented with a three-part fracture, and 8 presented with a four-part fracture. Based on the AO/OTA classification, 35 patients were type 11-A2 (extraarticular, unifocal, 2-part, surgical neck fracture), 1 was type 11-A3 (unifocal, 2-part, extraarticular vertical fracture), 11 were type 11-B (extraarticular, bifocal, 3-part), and 15 were type 11-C (articular or 4-part fracture). Among the 62 patients, 30 (48.4%) presented with confirmed medial comminution in the fracture pattern according to the pre-operative radiograph and CT images. The average duration of the follow-up period was 14.84 months (range, 12-72).

The mean surgical time was 142.6 minutes (range, 70-125). Sixteen cases were augmented with bone chips or substitutes for substantial bone defects, and in 10 cases cuff suture augmentation was performed for additional stability and to avoid secondary varus collapse. There were no intra-operative complications, including iatrogenic neurovascular injuries. In 53 (85.5%) patients, medial support was achieved, as confirmed by the immediate post-operative radiographs (Table II). The average neck-shaft angle was 133.2° ± 6.90 according to the immediate post-operative radiographs, and 130.8° ± 10.52 according to the final radiograph. Five cases (8.1%) were regarded as varus malreduction, as their neck-shaft angles were less than 120° (mean NSA, 117.8°) based on immediate post-operative radiographs. As described in Table III, four cases (6.5%) were rated as secondary varus collapse (mean NSA change, 19.5°), either because their neck-shaft angles were more than 120° according to the immediate post-operative radiograph but eventually decreased to less than 120° based on the final radiograph, or because NSA change between immediate and final radiographs was greater than 10°. In total, nine cases showed varus states that were a combination of varus malreductions and collapses. It was confirmed that the position of the plate top was higher than the apex of the greater tuberosity in the nine cases (16.1% of all cases).

Post-operative infection occurred in one patient. After incision and drainage were performed and antibiotics were injected intravenously, the infection was addressed. Medical morbidities presented in five cases (pneumonia in two patients, acute renal failure in one patient, exacerbation of COPD in one patient, and heart failure in one patient). Among them, one patient died during the follow-up. A delayed union occurred in one patient, while non-union occurred in another. In the case of the delayed union, it was observed six months after the surgery without any additional procedure, like bone grafting. In the case of non-union, even though revision surgery due to accompanying mechanical failure was advised, the patient refused this intervention. Although proximal migration of the greater tuberosity was observed in three patients, union was present at a slightly displaced position, without revision surgery, at three months post-operatively.

Mean VAS for pain was 1.87 ± 2.33, SSV was 79.71 ± 7.19, and ASES score was 73.32 ± 9.32 upon final clinical evaluation (Table IV). Nine patients (14.5%) complained of patient-defined post-operative stiffness. One of them wanted to address this stiffness, and thus, plate removal and arthroscopic capsular release were performed 15 months after the initial operation.

Participants were divided into two groups based on the time since the beginning of the surgeon's practice for the analysis of the impact of a learning curve on surgical performance: Group A (32 patients) consisted of patients who underwent operations by surgeons within the first year of practice, and Group B (30 patients) consisted of patients who underwent operations by surgeons in the following years of practice.

There were no statistically significant differences between the two groups in the demographic data, including age, sex, arm involved, BMD, days from trauma to surgery, and follow-up duration. For the fracture pattern between the two groups, the distribution of fracture type (Neer's and AO/OTA) and the presence of medial comminution at the time of the injury did not present a statistically significant difference (53.1%, 43.3%, p = 0.441). Surgical time was shorter in Group B (mean, 132.5 min; range, 119-143) than in Group A (mean, 152.1 min; range, 115-149). However, the difference in the surgical time was not statistically significant (p=0.154).

In the initial neck-shaft angle and the number of cases of varus malreduction immediately after the operation, there were no statistically significant differences between the two groups (p=0315, p=0.198, respectively). Comparison of the initial and final radiographs revealed more cases with varus collapse in Group A than in Group B, although the difference was not statistically significant. Radiographic data between Groups A and B immediately after the index surgery at the final follow-up were described in Tables II and III.

Interestingly, the incidence of medial support achieved immediately after the operation was greater in Group B than in Group A, and the difference was statistically significant (p=0.027). In Group A, 24 (75%) patients achieved confirmed medial support according to the immediate post-operative radiographs. Two patients had an anatomic reduction of the medial cortex in cases without medial

Table I: Patient demography.

	Total	Group A	Group B	p-value
Number	62	32	30	
Age (years)	64.6 ± 14.12	67.5 ± 12.62	61.5 ± 15.16	0.097
Sex (male : female)	26:36	15:17	11:19	0.416
Involved side (right : left)	32:30	13:19	19:11	0.083
Bone marrow density (T-score)	-2.8 ± 1.16	-2.9 ± 1.32	-2.7 ± 0.70	0.541
Days from injury to surgery	6.3 ± 3.50	7.1 ± 4.10	5.5 ± 2.56	0.077
Neer classification				
2-part fracture	35	16	19	0.558
3-part fracture	19	11	8	
4-part fracture	8	5	3	
AO/OTA classification (Humerus, proximal end segment, 11)				
11-A2 (11A2.1/A2.2/A2.3)	35 (8/12/15)	17 (3/7/7)	18 (5/5/8)	0.860
11-A3	1	0	1	
11-B	11	6	5	
11-C (11C1.1/11C3.1)	15 (7/8)	9 (4/5)	6 (3/3)	
The presence of medial comminution	30 (48.4%)	17 (53.1%)	13 (43.3%)	0.441
Surgical time (min)	142.6 ± 53.00	152.1 ± 52.10	132.5 ± 53.00	0.154
Follow-up duration (months)	14.84 ± 15.02	13.2 ± 9.50	16.4 ± 19.29	0.410

Notes: This study included 2-part surgical neck fractures which were deemed unstable, such as with less than 50% contact between the shaft and the head fragment, varus or valgus displacement, or extensive metaphyseal comminution. Data are reported as mean ± standard deviation or number (%). p-value <0.05 is considered statistically significant (asterisk).

Table II: Radiographic evaluations between Groups A and B immediately after the operation.

	Total	Group A	Group B	p-value
The presence of medial support	53 (85.5%)	24 (75%)	29 (96.7%)	0.027*
Initial NSA	133.2 ± 6.90	132.4 ± 7.93	134.1 ± 5.59	0.315
Varus malreduction	5 (8.1%)	4 (12.5%)	1 (3.3%)	0.198
High position of plate	10 (16.1%)	9 (28.1%)	1 (3.3%)	0.008*
Screw penetration	0	0	0	

Notes: Initial NSA; neck-shaft angle immediately after the operation. Data are reported as mean ± standard deviation or number (%). p-value <0.05 is considered statistically significant (asterisk).

Table III: Radiographic evaluations between Groups A and B at the final follow-up.

	Total	Group A	Group B	p-value
Final NSA	130.8 ± 10.52	128.4 ± 13.13	133.4 ± 5.90	0.056
Secondary collapse	4 (6.5%)	3 (9.4%)	1 (3.3%)	0.331
Reduction loss of tuberosity	3	1	2	0.475
Mechanical failure	1	1	0	0.516
Non-union	1	1	0	0.516

Table IV: Clinical outcomes between Groups A and B.

	Total	Group A	Group B	p-value
Final VAS for pain	1.87 ± 2.33	1.87 ± 2.33	1.74 ± 1.19	0.828
Final SSV	79.71 ± 7.19	79.64 ± 6.34	79.80 ± 8.23	0.937
Final ASES score	73.32 ± 9.32	73.91 ± 7.54	72.63 ± 11.18	0.637
Patient-defined stiffness (%)	9 (14.5%)	4 (12.5%)	5 (16.7%)	0.457

Notes: VAS; visual analogue scale, SSV; Subjective shoulder value, ASES; American shoulder and elbow surgeons. Data are reported as mean ± standard deviation or number (%). p-value <0.05 is considered statistically significant (asterisk).

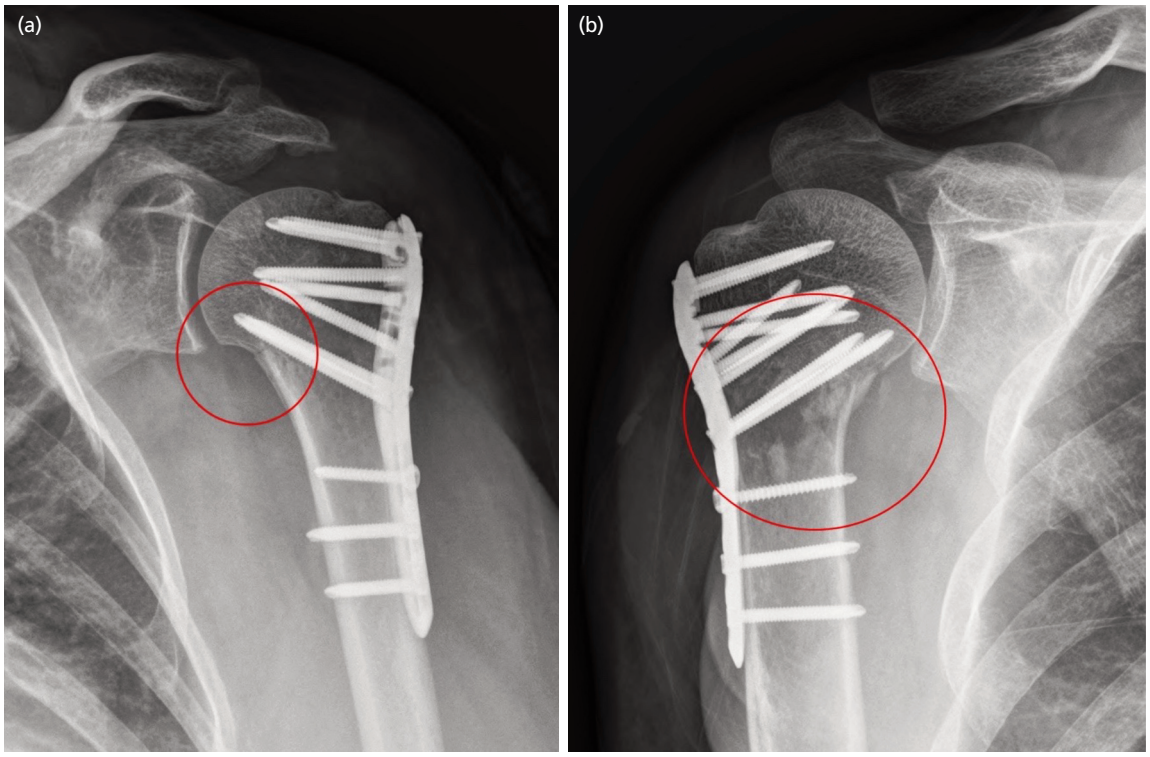

Fig. 1: (a) Anteroposterior radiograph showing the medial support, defined as an anatomical reduction and alignment of the medial column in cases where there is no medial comminution. (b) In cases with medial comminution, it is defined as an achievement of the insertion of two or three inferomedial screws or reduction with the intended slight impaction, or both.

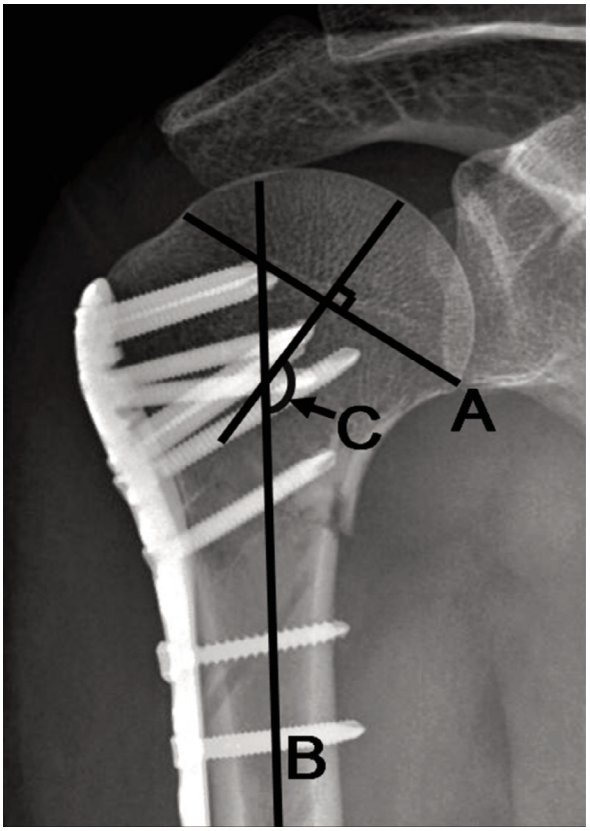

Fig. 2: Measurement of neck-shaft angle (angle C), which is the angle between the vertical line to the line that connects both the articular segments of the humeral head (line A) and the line that connects the axis of the humeral shaft (line B) in the AP view of the plain radiograph.

comminution, while 14 patients had 2 or 3 inferomedial screws placed and 8 patients had both in cases with medial comminution. Importantly, 29 (96.7%) patients in Group B were confirmed to have achieved medial support. Four patients had an anatomic reduction of the medial cortex in cases without comminution, while 14 had 2 or 3 inferomedial screws placed and 10 patients had both in cases with medial comminution. Similarly, patients with plate placement higher than the apex of the greater tuberosity immediately after the operation were significantly more in Group A than in Group B (p=0.008). Patients with screw penetration through the articular surface of the humeral head were not present in either of the two groups.

We found that, although more cases showed the differences in the radiological findings (although some factors were not statistically significant) in Group A than in Group B, the two groups showed no difference in clinical results (PVAS, SSV, and ASES score) and post-operative stiffness (p=0.828, p=0.937, p=0.637, and p=0.457, respectively) at the final follow-up.

DISCUSSION

The most interesting finding of this study was that the medial support for stability and maintenance of fracture reduction and the position of the plate, which is associated with possible complications, showed more significant improvement during the learning curve for locking plate fixation in complex proximal humeral fractures compared to operations performed by orthopaedic shoulder surgeons who have just started their practices. However, clinical and radiological outcomes, such as varus malposition immediately after surgery or secondary collapse over time, and complications, including reduction loss of tuberosity, mechanical failure, and non-union, did not reach statistical significance in groups of patients split on the basis of the first year and subsequent year of practice.

Developments in the implant for fracture fixation and surgical techniques have led to significant improvements in clinical and functional outcomes[1]. The locking plate provides better rotational and angular stability, especially in osteoporotic bone, and allows early mobilisation. Most of the proximal humeral fractures are strongly related to osteoporosis and old age; thus locking plate fixation is currently recommended as the standard procedure for fracture types requiring surgery[5]. Nonetheless, surgical treatment using a locking plate fixation for complex and unstable proximal humeral fractures is still reported to have a relatively high complication rate[6,8]. Furthermore, it is important to acknowledge that the outcome of surgical treatment of the proximal humeral fracture is influenced by sufficient experience and techniques such as exposure, reduction, and the insertion of plates and screws. These issues might make it difficult for inexperienced surgeons to properly perform ORIF using a locking plate. In particular, varus conditions (total of 9 cases), including immediate post-operative malreduction and secondary varus collapse, and inadequate positioning of the plate (total of 9 cases) were common complications in this study.

The restoration of anatomical alignment following locking plate fixation of proximal humeral fractures is the basis of the stability and maintenance of fracture reduction[10-15]. It is also important for the healing of the fracture and to prevent avascular necrosis of the humeral head by maintaining the blood supply of the proximal fragments via branches of the posterior circumflex artery. Nonetheless, sometimes the restoration of bony alignment during the intra-operative process for proximal humeral fracture, even in the case of a surgical neck fracture, is not possible. This can lead to secondary varus collapse or reduction loss. In the more complex fracture patterns, especially in cases with medial cortical comminution or severe displacement, many studies suggest that mechanical stability of the inferior-medial region of the proximal humerus appears to be important for more stable support and better post-operative outcomes after locking plate fixation. Gardner *et al*[12] first described that locking plates in general do not appear to be a panacea for proximal humeral fracture and are unable to support the medial column without anatomic reduction or carefully placed inferior-medial screws. They proposed that adequate medial support through medial cortical contact or, in the case of medial comminution, placing the locking screws specifically into the inferior-medial aspect of the humeral head fragment plays an important role in maintaining fracture stability. This importance of medial support for unstable and complex proximal humeral fracture has been supported by both clinical and biomechanical studies[2,3,7].

However, this is difficult to achieve during the early clinical period of young beginner surgeons. Comparison of the first and subsequent two years of practice in our study showed statistically significant differences in the presence of the medial support according to immediate post-operative radiographs. In the first year of practice, less medial support was observed. In other words, a learning curve for surgical performance is necessary to achieve medial support during the intra-operative procedure. During the learning curve for novice orthopaedic surgeons who performed locking plate fixation in a proximal humeral fracture, we demonstrated that achievement of medial support showed a statistically significant improvement.

Surgeons inexperienced in surgical procedures are in the early phase of their learning curve, and numerous peers speculate whether surgical experience has a substantial impact on surgical results. The learning curve of surgical performance is influenced by various factors and is considered in several ways. As described in the study by Hopper *et al.*[16], measures of learning related to surgical

performance can be classified into two categories: surgical process and patient outcome. Several studies have set surgical processes such as operative time, blood loss, technical adequacy, and patient outcomes such as duration of hospitalisation and rate of complications as the primary variables to measure changes during learning curves. Recognition of these learning curves inherent to technical mastery is important in the field of orthopaedic surgery. Meanwhile, the studies in the orthopaedic field mainly focused on replacement surgery, including arthroplasty, which is a planned elective surgery and consistently well-defined in most procedures[21-23]. Studies on learning curves in surgery using arthroscopic instruments, such as arthroscopic rotator cuff repair or Latarjet procedures, have also been published[24-26].

Although some studies, especially on the lower extremity, have reported the learning curve for fracture treatment[27,28], few have explored the learning curve in the surgical treatment of proximal humeral fractures. Clinical evidence is still insufficient to support the existence of a surgical learning curve for proximal humeral fractures. To the best of our knowledge, only two studies[29,30] have evaluated the learning curve for the surgical treatment of the proximal humeral fracture; one study determined the presence of a learning curve in reverse shoulder arthroplasty for proximal humeral fracture, and the other was similar to our research on open reduction and locking plate fixation. Blaas *et al.*[29] found that the learning curve for reverse shoulder arthroplasty for proximal humeral fracture, based on functional outcome, complications, and operation time, is achieved after performing 20 procedures. However, even in the case of similar fractures, it stands to reason that there will be different learning curves for different surgical options. Moreover, the changing trends of operative time or blood loss as a reference to evaluate the learning curve may be more suitable for some quantified operations through a fixed surgical process, such as total knee, hip or shoulder arthroplasty. In addition, the complications and outcomes were found to be influenced by a variety of fracture- or patient-related factors. In our study, the reason for determining the medial support as the primary variable to evaluate the learning curve is based on this clinical background. Medial support is a well-defined and validated factor that is directly related to outcome, and the main goal of an orthopaedic surgeon who performs ORIF for proximal humeral fracture is to obtain medial support. Furthermore, medial support can be objectively evaluated as a radiological parameter. Egol *et al.*[30] prospectively compared the radiographic data, functional outcomes, and complications between the surgeon's first 81 patients and the subsequent 80 patients for 161 consecutive patients with proximal humeral fractures treated with locked plates by a single surgeon. There were no statistical differences in functional outcome and the rates of complications, including screw penetration; however, head-shaft angles were slightly smaller in patients treated earlier in the surgeon's career. According to the authors, no significant learning curve was present with regard to the treatment of proximal humeral fractures, as a notable difference in complication rates between patients treated earlier and later in the surgeon's career was absent. The results of their study were similar to our results. Unlike our study, which had a shorter split period, their study was designed to compare the two groups of periodic splitting based on a period of five years. Although there may be differences depending on the number of cases, five years is likely the point at which the learning curve has already been passed. It is questionable whether this period reflects the early phase of the learning curve in their study. Moreover, their study focused on complications including screw penetration or cut-out, radiographic alignment parameters, and clinical outcomes. These variables showed similar results in our research. However, our study focused on medial support, which was not analysed in their research, and showed a meaningful difference within a shorter learning curve period.

The learning curve is an extremely complex concept. Even in the case of diagnosis involving the same fracture classification, it is difficult to quantify the learning curve of surgical performance for the treatment of the fracture, because the characteristics of displacement, comminution, bone loss, and bone quality vary significantly between fracture cases. Furthermore, the learning curve can be associated with the volume and frequency of surgical work, complexity of the fracture, and relative roles of the surgical assistants. This may be in line with the fact that experienced surgeons are subjected to trial and error when they are challenged with more serious cases. A similar finding was reported in a study on the learning curve for arthroscopic rotator cuff repair by Lim *et al*.[24]. They reported that the retear rate of large to massive rotator cuff tears, especially with significant retraction and immobility, did not improve even though the surgeon's skill continued to improve over time. In addition, a systematic review by Walch *et al.*[23] reported that surgeons' experience over time probably led to significantly modified patient selection to maintain the indications associated with the best functional outcomes, while decreasing the indications associated with bad functional outcomes coupled with a high complication rate. Our research focused more on identifying the surgical factors that improved during the learning curve, based on periodic splitting of two groups between the first and subsequent years of practice, rather than analysing the timing or number needed for the success rate or functional improvement during the learning curve. Although there were no differences between various parameters, including functional outcomes, a statistically significant difference was observed between the achievement of early and late medial support. The improvement in obtaining medial support could directly indicate the progress in technical skills required for surgery, and it was determined that the learning curve was present

and skills were developed through this period. Lack of change in functional outcomes between the two groups is thought to be because the sample size that is needed to reflect the clinical impact of medial support is relatively low, or because medial support alone may be insufficient to drive functional outcomes, and not due to the absence of a learning curve. It could also be due to the fellowship training being understood and integrated with regard to the principles and the perils of locking plate and fracture management.

ORIF in the proximal humeral fracture is one of the most commonly performed procedures in the shoulder; therefore, evaluation of the surgical learning curve may be worthy and meaningful. The recognition of a reference as a significant learning curve effect will play an important role in emphasising the need to rapidly focus and safely overcome the learning curve. The medial support is a comprehensive result that combines a series of essential processes, such as soft tissue handling, fracture identification, fragment reduction, implant positioning, fixation, among others, in the surgical treatment process for proximal humeral fractures. It is also known to have a direct connection to the results after surgery. Therefore, medial support may reflect better surgical proficiency in the overall surgical process for fracture treatment and be a consequence of the learning curve. The result of our study will provide more accurate information to monitor and guide individual surgical performance and help in identifying improvement areas on an ongoing basis. This could also rapidly improve surgical proficiency, as well as the efficacy and safety of treatment and decrease medical costs.

Our study has several limitations. First, it is a retrospective study with a relatively small sample size. However, during the learning curve, which only occurs during a limited period of time, the number of patients that are treated by one surgeon is limited. Despite conducting a multicentre study to overcome the small sample size, we did not obtain a sample size sufficient to reflect the learning curve according to the number of cases. Additionally, as the number of cases increased, surgeons tended to refine and modify their surgical techniques faster than expected to maximise surgical outcomes and minimise complications. Therefore, in a large volume study there will be no choice but to evaluate more novice surgeons and hence, additional research may be needed. Second, this study involved patients treated by three shoulder surgeons working at different hospitals, which could introduce a selection bias. In addition, the techniques of each surgeon were different in detail. Nevertheless, they are orthopaedic surgeons who have completed their training at the same hospital, during similar time frames, and share common surgical concepts with each other. The primary variable in the study is the medial support as a comprehensive result that combines a series of essential processes. All evaluations were re-evaluated by an independent surgeon using the most uniform method. Finally, our study did not include patients treated with ORIF using a locking plate with strut graft augmentation. This method is a viable option for minimising the risk of failure for ORIF using a locking plate; however, it presents different biomechanics from the locking plate fixation without the graft augmentation.

CONCLUSION

The most interesting finding of this study was that the surgical performance associated with achieving medial support for locking plate fixation in a complex proximal humeral fracture improved during the learning curve of the inexperienced surgeon. The medial support is a comprehensive result that combines a series of essential processes in the surgical treatment for proximal humeral fractures; hence, the medial support reflects better surgical proficiency in the overall surgical process performed to treat fractures and is a consequence of the learning curve. Recognition of the medial support as a reference for a significant learning curve effect plays a role in emphasising the need to rapidly focus and safely overcome the learning curve. No significant difference in the clinical outcomes, radiological errors, and complications between the early and late one-year period groups is observed. This may be due to the relatively low sample size, which could reflect the clinical impact of medial support or the effect of the fellowship training provided with regard to the principles and the perils of locking plate and fracture management.

ACKNOWLEDGEMENT

The authors thank Soo-Hyun Lee in the medical information library of National Medical Center for her co-operation.

CONFLICT OF INTEREST

The authors declare that there are no potential conflicts of interest.

REFERENCES

1. Kim H, Song SJ, Jeon IH, Koh KH. Inter-rater agreement among shoulder surgeons on treatment options for proximal humeral fractures among shoulder surgeons. *Clin Shoulder Elb.* 2022; 25(1): 49-56. doi: 10.5397/cise.2021.00416
2. Lescheid J, Zdero R, Shah S, Kuzyk PR, Schemitsch EH. The biomechanics of locked plating for repairing proximal humerus fractures with or without medial cortical support. *J Trauma.* 2010; 69(5): 1235-42. doi: 10.1097/TA.0b013e3181beed96
3. Walsh S, Reindl R, Harvey E, Berry G, Beckman L, Steffen T. Biomechanical comparison of a unique locking plate versus a standard plate for internal fixation of proximal humerus fractures in a cadaveric model. *Clin Biomech (Bristol).* 2006; 21(10): 1027-31. doi: 10.1016/j.clinbiomech.2006.06.005
4. Kim DY, Kim TY, Hwang JT. PHILOS plate fixation with polymethyl methacrylate cement augmentation of an osteoporotic proximal humerus fracture. *Clin Shoulder Elb.* 2020; 23(3): 156-8. doi: 10.5397/cise.2020.00206
5. Mease SJ, Kraeutler MJ, Gonzales-Luna DC, Gregory JM, Gardner MJ, Choo AM. Current Controversies in the Treatment of Geriatric Proximal Humeral Fractures. *J Bone Joint Surg Am.* 2021; 103(9): 829-36. doi: 10.2106/JBJS.20.00665
6. Robinson CM, Stirling PHC, MacDonald DJ, Strelzow JA, Goudie EB. Open Reduction and Long Locking Plate Fixation of Complex Proximal Humeral Metadiaphyseal Fractures. *J Bone Joint Surg Am.* 2020; 102(24): 2146-56. doi: 10.2106/JBJS.20.00372
7. Pawaskar AC, Lee KW, Kim JM, Park JW, Aminata IW, Jung HJ, *et al.* Locking plate for proximal humeral fracture in the elderly population: serial change of neck shaft angle. *Clin Orthop Surg.* 2012; 4(3): 209-15. doi: 10.4055/cios.2012.4.3.209
8. Robinson CM, Stirling PHC, Goudie EB, MacDonald DJ, Strelzow JA. Complications and Long-Term Outcomes of Open Reduction and Plate Fixation of Proximal Humeral Fractures. *J Bone Joint Surg Am.* 2019; 101(23): 2129-39. doi: 10.2106/JBJS.19.00595
9. Yahuaca BI, Simon P, Christmas KN, Patel S, Gorman RA 2nd, Mighell MA, et al. Acute surgical management of proximal humerus fractures: ORIF vs. hemiarthroplasty vs. reverse shoulder arthroplasty. J Shoulder Elbow Surg. 2020; 29(7S): S32-40. doi: 10.1016/j.jse.2019.10.012
10. Wang Q, Sheng N, Rui B, Chen Y. The neck-shaft angle is the key factor for the positioning of calcar screw when treating proximal humeral fractures with a locking plate. *Bone Joint J.* 2020; 102-B(12): 1629-35. doi: 10.1302/0301-620X.102B12.BJJ-2020-0070.R1
11. Ponce BA, Thompson KJ, Raghava P, Eberhardt AW, Tate JP, Volgas DA, *et al.* The role of medial comminution and calcar restoration in varus collapse of proximal humeral fractures treated with locking plates. *J Bone Joint Surg Am.* 2013; 95(16): e113(1-7). doi: 10.2106/JBJS.K.00202
12. Gardner MJ, Weil Y, Barker JU, Kelly BT, Helfet DL, Lorich DG. The importance of medial support in locked plating of proximal humerus fractures. *J Orthop Trauma*. 2007; 21(3): 185-91. doi: 10.1097/BOT.0b013e3180333094
13. Burke NG, Kennedy J, Cousins G, Fitzpatrick D, Mullett H. Locking plate fixation with and without inferomedial screws for proximal humeral fractures: a biomechanical study. *J Orthop Surg (Hong Kong).* 2014; 22(2): 190-4. doi: 10.1177/230949901402200215
14. Xu J, Zhan S, Ling M, Jiang D, Hu H, Sheng J, *et al.* How can medial support for proximal humeral fractures be achieved when positioning of regular calcar screws is challenging? Slotting and off-axis fixation strategies. *J Shoulder Elbow Surg.* 2022; 31(4): 782-91. doi: 10.1016/j.jse.2021.08.033
15. Zhang W, Zeng L, Liu Y, Pan Y, Zhang W, Zhang C, *et al.* The mechanical benefit of medial support screws in locking plating of proximal humerus fractures. *PLoS One.* 2014; 9(8): e103297. doi: 10.1371/journal.pone.0103297
16. Hopper AN, Jamison MH, Lewis WG. Learning curves in surgical practice. *Postgrad Med J.* 2007; 83(986): 777-9. doi: 10.1136/pgmj.2007.057190
17. Ahn J, Kim TY, Kim TW, Jeong BO. Learning Curve for Open Reduction and Internal Fixation of Displaced Intra-articular Calcaneal Fracture by Extensile Lateral Approach Using the Cumulative Summation Control Chart. *Foot Ankle Int.* 2019; 40(9): 1052-9. doi: 10.1177/1071100719850149

18. Kempton LB, Ankerson E, Wiater JM. A complication-based learning curve from 200 reverse shoulder arthroplasties. *Clin Orthop Relat Res.* 2011; 469(9): 2496-504. doi: 10.1007/s11999-011-1811-4
19. Meinberg EG, Agel J, Roberts CS, Karam MD, Kellam JF. Fracture and Dislocation Classification Compendium-2018. *J Orthop Trauma.* 2018; 32 Suppl 1: S1-170. doi: 10.1097/BOT.0000000000001063
20. Neer CS 2nd. Displaced proximal humeral fractures. I. Classification and evaluation. *J Bone Joint Surg Am.* 1970; 52(6): 1077-89.
21. Mahure SA, Teo GM, Kissin YD, Stulberg BN, Kreuzer S, Long WJ. Learning curve for active robotic total knee arthroplasty. *Knee Surg Sports Traumatol Arthrosc.* 2022; 30(8): 2666-76. doi: 10.1007/s00167-021-06452-8
22. Sarpong NO, Herndon CL, Held MB, Neuwirth AL, Hickernell TR, Geller JA, *et al.* What Is the Learning Curve for New Technologies in Total Joint Arthroplasty? A Review. *Curr Rev Musculoskelet Med.* 2020; 13(6): 675-9. doi: 10.1007/s12178-020-09671-7
23. Walch G, Bacle G, Lädermann A, Nové-Josserand L, Smithers CJ. Do the indications, results, and complications of reverse shoulder arthroplasty change with surgeon's experience? *J Shoulder Elbow Surg.* 2012; 21(11): 1470-7. doi: 10.1016/j.jse.2011.11.010
24. Lim TK, Bae KH, Choi YS, Kim JH, Yoo JC. Clinical outcome and repair integrity after arthroscopic rotator cuff repair significantly improved during the surgeon's learning curve. *J Shoulder Elbow Surg.* 2021; 30(8): 1881-90. doi: 10.1016/j.jse.2020.10.031
25. McColl AH, Lam PH, Murrell GAC. Are we getting any better? A study on repair integrity in 1600 consecutive arthroscopic rotator cuff repairs. *JSES Open Access.* 2019; 3(1): 12-20. doi: 10.1016/j.jses.2019.01.002
26. Valsamis EM, Kany J, Bonnevialle N, Castricini R, Lädermann A, Cunningham G, *et al.* The arthroscopic Latarjet: a multisurgeon learning curve analysis. *J Shoulder Elbow Surg.* 2020; 29(4): 681-8. doi: 10.1016/j.jse.2019.10.022
27. Altintas B, Biber R, Bail HJ. The learning curve of proximal femoral nailing. *Acta Orthop Traumatol Turc.* 2014;48(4):396-400. doi: 10.3944/AOTT.2014.13.0056
28. Walton R, Theodorides A, Molloy A, Melling D. Is there a learning curve in foot and ankle surgery? *Foot Ankle Surg.* 2012; 18(1): 62-5. doi: 10.1016/j.fas.2011.03.007
29. Blaas LS, Yuan JZ, Lameijer CM, van de Ven PM, Bloemers FW, Derksen RJ. Surgical learning curve in reverse shoulder arthroplasty for proximal humerus fractures. *JSES Int.* 2021; 5(6): 1034-41. doi: 10.1016/j.jseint.2021.07.008
30. Egol KA, Shulman BS, Belayneh R, Karia RJ, Zuckerman JD. Does a Learning Curve Exist for the Surgical Treatment of Proximal Humerus Fractures? *Bull Hosp Jt Dis.* 2018; 76(4): 265-9.

Cite this article:

Lim TK, Koh KH, Lee TH, Shon MS. The Impact of the Learning Curve on Surgical Performance Focused on Achieving Medial Support in Complex Proximal Humeral Fracture: ORIF using a Locking Plate. *Malays Orthop J.* 2026; 20(3): 59-69. doi: 10.5704/MOJ.2611.007