doi: https://doi.org/10.5704/MOJ.2611.015

Emphysematous Osteomyelitis of Ilium Associated with Low Back Pain: A Case Report

Panda PK[1], MS Ortho, **Dalei TR[1]**, MS Ortho, **Pattnaik D[2],** MD Microbiol

[1]Department of Orthopaedics, Veer Surendra Sai Institute of Medical Sciences And Research (VIMSAR), Sambalpur, India
[2]Department of Microbiology, Veer Surendra Sai Institute of Medical Sciences And Research (VIMSAR), Sambalpur, India



This is an open-access article distributed under the terms of the Creative Commons Attribution License, which permits unrestricted use, distribution, and reproduction in any medium, provided the original work is properly cited

Date of submission: 29th September 2025
Date of acceptance: 20th December 2025

ABSTRACT

Iliac osteomyelitis constitutes a remarkable difficulty for an orthopaedist in early diagnosis and management. Abscess formation and bony destruction are common findings in pelvic osteomyelitis. The presence of intraosseous gas in the ilium is a concern due to its potentially fatal consequences, requiring urgent diagnosis and prompt management. We report the case of a 14-year-old boy initially diagnosed with low backache with radiculopathy to the right knee, who visited our institute for further evaluation. Radiological assessment demonstrated abscess under the ilium. Abscess culture isolated methicillin-resistant *Staphylococcus aureus* and *Klebsiella species*. The patient underwent abscess drainage and culture-sensitive antibiotics for four weeks, following which he made a full recovery. Emphysematous Osteomyelitis (EO) presenting as an intraosseous gas-occupying lesion needs to be addressed with great precision and aggressive antibiotic therapy with surgical debridement to prevent potential life-threatening complications.

Keywords:
emphysematous osteomyelitis, iliac osteomyelitis, intraosseous gas, Staphylococcus aureus, Klebsiella

INTRODUCTION

Acute hematogenous osteomyelitis is a rare occurrence[1]. The incidence of pelvic osteomyelitis in childhood is largely undocumented, and permanent disability is a concern in 3.4% of cases[1]. A history of antecedent trauma is also absent in such cases, leading to delayed diagnosis due to lack of classical clinical signs of osteomyelitis[1]. The infection commonly results from hematogenous spread. *Staphylococcus* is the most frequently isolated organism, but the infection can be polymicrobial[2].

A sporadic form of the disease, namely Emphysematous Osteomyelitis (EO), caused by gas forming bacteria, was first described by Kumar *et al* in 1981, and only 57 cases have been reported to date in the medical literature[3]. According to research published by Kihiczak and Epstein, the occurrence of intraosseous gas in flat bones of the appendicular skeleton is rare in the absence of antecedent events such as trauma or surgery and suggests the presence of EO[3].

CASE REPORT

The subject was a boy aged 14 years who visited our outpatient facility complaining of low back pain radiating to the right knee for two months. He had previously received analgesics for the same symptoms at a local hospital. There was no history of fever, chronic cough, weight loss, or urinary complaints. Vitals were in the normal range. Examination revealed an antalgic gait with a Trendelenburg component on the right side, increased lumbar lordosis, and a fixed flexion deformity of 20° at the right hip. Examination of the lower spine did not reveal any localised spinal tenderness or swelling. Movements of the spine were normal. Straight leg raise test on both sides was negative, with no distal neurovascular deficit in bilateral lower limbs. The right sacroiliac joint and soft spot lateral to it were tender to palpation. The right anterior joint line was non-tender. Movements of both hips were normal except for loss of extension at the right hip. Abdominal examination was normal.

Plain radiographs of the lumbosacral spine and pelvis with bilateral hips were normal (Fig. 1). However, ultrasonography revealed a focal collection deep to the gluteus medius and iliacus muscles, with irregularity of the right iliac bone suggestive of osteomyelitis. Blood

Corresponding Author: Pritam Kumar Panda, Department of Orthopaedics, Veer Surendra Sai Institute of Medical Sciences And Research (VIMSAR), Sambalpur, Burla, Odisha 768017, India
Email: pritampanda57@gmail.com

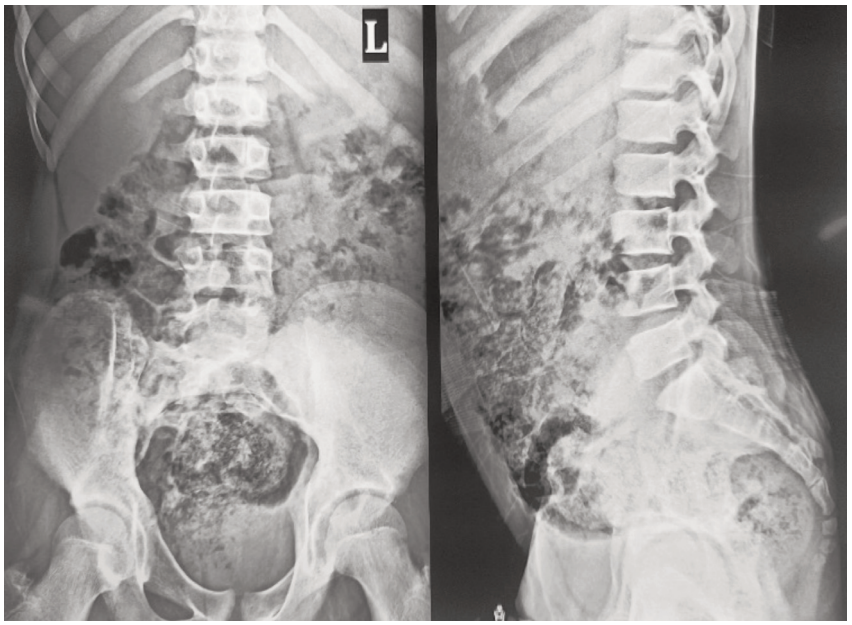

Fig. 1: Showing a plain radiograph of the lumbosacral spine with pelvis with bilateral hips in anteroposterior and lateral views.

parameters showed leucocytosis with neutrophilia; the sedimentation rate was 110mm, with a CRP of 68.07mg/L. Urine analysis was normal. Non-contrast computed tomography (NCCT) of the pelvis revealed tiny pockets of air collection involving the right iliac bone with lytic changes of the right sacroiliac joint suggestive of osteomyelitis (Fig. 2). Similar variations were established by MRI with abscess delineation and extent (Fig. 3). There was no sign of avascular necrosis of the hips.

The patient was placed on bed rest and skin traction. Ultrasound-guided aspiration of the abscess was performed through the subgluteal plane, and the aspirate was sent for microbiological analysis. Gram staining demonstrated Gram-positive cocci and Gram-negative bacilli, while staining for acid-fast bacilli was negative. Aerobic and anaerobic growth yielded *Staphylococcus aureus* and *Klebsiella spp.* Blood and urine cultures were negative. The patient subsequently underwent open debridement and drainage of the abscess in the right subpsoas plane under anaesthesia. Intraoperative specimens were also sent for microbiological analysis.

Following surgery, the patient received broad-spectrum intravenous antibiotic therapy with a cephalosporin and metronidazole for four days. Treatment was subsequently changed to linezolid according to the culture and susceptibility results and continued for a further three weeks. His symptoms resolved and inflammatory markers normalised following antibiotic treatment. He was discharged on oral antibiotics for four weeks and reviewed six weeks after completing treatment.

At follow-up, the patient was asymptomatic and walked with a normal gait. The fixed flexion deformity of the right hip had resolved, and the hip had a full, pain-free range of motion. The surgical wound showed satisfactory healing.

DISCUSSION

Emphysematous osteomyelitis (EO), first described by Ram *et al* in 1981, is a rare life-threatening condition characterised by the presence of intraosseous gas within the bone[4]. The presence of intraosseous gas without any prior event like trauma, surgery, or degenerative disease is virtually pathognomonic of EO[3]. However, its presence may be indicative of secondary conditions and non-infectious aetiologies such as degenerative diseases, intraosseous cysts, trauma from bone biopsy, osteonecrosis from malignancy like acute myeloid leukaemia, etc[3].

Since its first description in the literature, only 57 cases have been reported worldwide in the medical literature[3]. The disease predominantly involves the axial skeleton, like the vertebrae, sacrum, sternum, and ribs, and less commonly the extra-axial skeleton, like the femur, tibia, pelvis, and tarsal and metatarsal bones, in that order[3]. There is no gender-specific correlation to the disease, and the mean age of affection was 54.7 years, affecting the middle-aged to elderly population with some preexisting disease, most likely a history of type 2 diabetes, malignancy, alcoholism, steroid therapy, Crohn's disease, sickle cell anaemia, immunosuppression, etc[3]. It has been documented that no preexisting illness was seen in 17% of cases of EO[3].

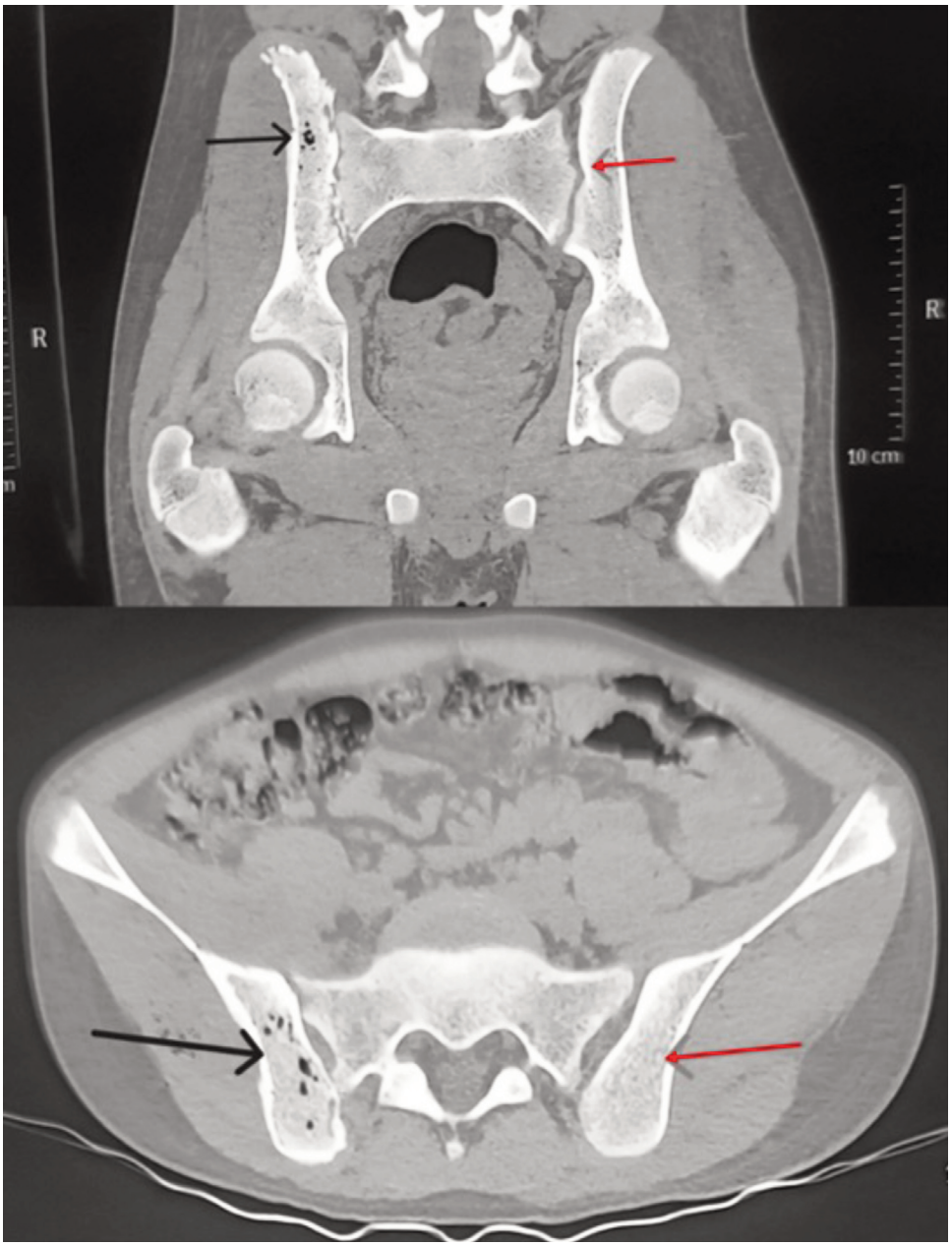

Fig. 2: showing intraosseous air in the right posterior iliac bone with destruction of the right SI joint (black arrow) compared to the normal SI joint on the left side (red arrow) in coronal and axial NCCT of the pelvis with bilateral hips.

EO usually spreads through a hematogenous route, with most of the cases being monomicrobial. The most common ones belong to the Enterobacteriaceae family, which includes *E. coli* and *Klebsiella*. Anaerobic involvement like *Fusobacterium, Peptostreptococcus,* and *Clostridium,* has been documented. *Staphylococcus aureus* is commonly associated with vertebral osteomyelitis[3].

Non-contrast Computed tomography (NCCT) plays a central role in diagnosing EO because it readily demonstrates intraosseous gas. MRI complements NCCT by defining marrow involvement, associated soft-tissue infection, and the extent of abscess formation.

Intraosseous gas is usually confirmed by the presence of two-to-five-millimetre tiny pockets of air, more than two in number, unevenly and unequally distributed inside the spongy portion of bone, termed as "pumice stone appearance," appearing as hyperlucent areas[3]. The possible mechanism of intraosseous gas formation is primarily the result of gas formation by the invading organism in the absence of any preexisting condition as described above and documented by Bielecki DK *et al*[4].

Although EO predominantly affects middle-aged and older adults with underlying illnesses, our patient was a previously healthy adolescent. The absence of fever, systemic symptoms, and recognised predisposing conditions may

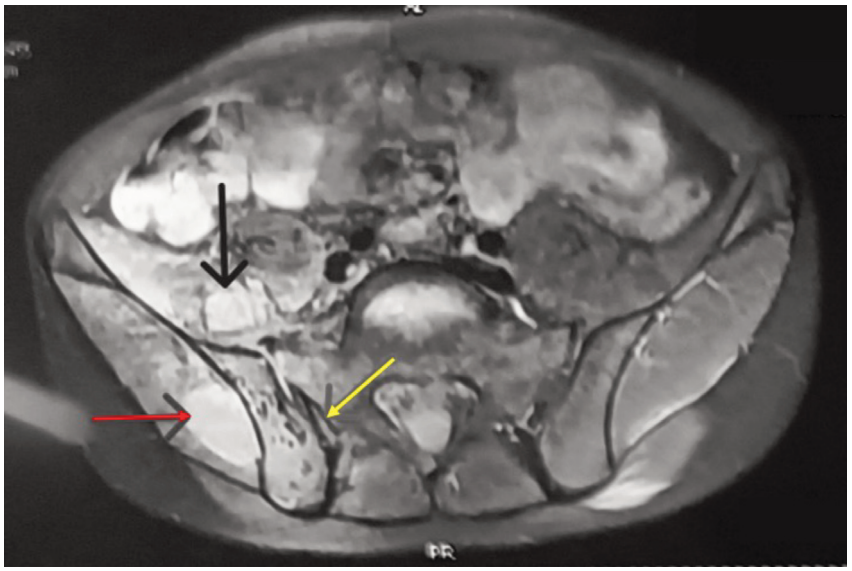

Fig. 3: showing an abscess in the right subgluteal region (yellow horizontal arrow) and subpsoas plane (black vertical arrow) and evidence of right SI joint destruction (red oblique arrow) in T2 MRI of the pelvis.

have contributed to the delayed recognition of infection. This case highlights the need to consider osteomyelitis in children with persistent back or hip pain, even when initial radiographs are normal and typical systemic features are absent.

Luey C *et al*[5] in their study reported a child aged 15 years who presented with non-responding low back and hip pain following the thirteenth day of RTA with tonsillitis, eventually diagnosed as a case of sacral EO, whereas no preexisting condition or traumatic event was observed in our case.

The presence of pathognomonic intraosseous gas collection in the posterior iliac bone with destruction of the sacroiliac joint as shown in NCCT and evidence of pus collection during surgical debridement confirms the diagnosis of EO. Samples from the pus showed polymicrobial growth of *Staphylococcus aureus* and *Klebsiella spp.* without any remote focus of infection, with negative blood cultures, and without any preexisting secondary condition.

Antibiotics to be used commonly are clindamycin, cephalosporins, and penicillin groups. Broad spectrum antibiotics with Gram-negative, Gram-positive, and anaerobic coverage must be initiated till the antibiotic sensitivity of the organism is confirmed[3]. The management modality for the disease is the same as for any other form of osteomyelitis, requiring early diagnosis and prompt antibiotic prophylaxis as per organism sensitivity.

Surgical drainage and debridement are indicated when there is a drainable abscess, necrotic tissue, extensive bone involvement, or an inadequate response to antimicrobial treatment. Antibiotic therapy is commonly continued for four to six weeks, with the route and duration individualised according to the organisms isolated, adequacy of source control, and clinical response[3]. Timely treatment is essential to limit local destruction and systemic complications.

In conclusion, we present a rare case of EO in a paediatric patient without any underlying chronic illness. Despite an initial delay in diagnosis and misdiagnosis, prompt recognition, urgent surgical debridement, and culture-guided antibiotic therapy remain essential for optimising survival, minimising complications, and reducing mortality.

CONFLICT OF INTEREST

The authors declare no potential conflict of interest.

REFERENCES

1. Zvulunov A, Gal N, Segev Z. Acute hematogenous osteomyelitis of the pelvis in childhood: Diagnostic clues and pitfalls. *Pediatr Emerg Care.* 2003; 19(1): 29-31. doi: 10.1097/00006565-200302000-00008
2. Kocialkowski C, Ryan W, Davis N. Case Report of Iliac Osteomyelitis in A Child, Presenting as Septic Arthritis of the Hip. *J Orthop Case Rep.* 2014; 4(4): 19-21. doi: 10.13107/jocr.2250-0685.217
3. Khan UH, Owas SZ, Bhat RQ, Mantoo S, Qadri SM, Mehfooz N, *et al.* Emphysematous Osteomyelitis: Literature Review and a Case Report. *J Clin Infect Dis Soc.* 2024; 2(2): 77-82. doi: 10.4103/CIDS.CIDS_62_23
4. Bielecki DK, Sartoris D, Resnick D, Van Lom K, Fierer J, Haghighi P. Intraosseous and intradiscal gas in association with spinal infection: report of three cases. *AJR Am J Roentgenol.* 1986; 147(1): 83-6. doi: 10.2214/ajr.147.1.83
5. Luey C, Tooley D, Briggs S. Emphysematous osteomyelitis: a case report and review of the literature. *Int J Infect Dis.* 2012; 16(3): e216-20. doi: 10.1016/j.ijid.2011.11.007

Cite this article:

Panda PK, Dalei TR, Pattnaik D. Emphysematous Osteomyelitis of Ilium Associated with Low Back Pain: A Case Report. *Malays Orthop J.* 2026; 20(3): 105-9. doi: 10.5704/MOJ.2611.015