doi: https://doi.org/10.5704/MOJ.2611.012

Missed Spontaneous Osteonecrosis of the Knee: A Case Report

Nasuruddin MH[1], MS Orth, **Selvaratnam V**[2], FRCS, **Ayob KA**[3], MS Orth, **Abbas AA**[2], MS Orth

[1]Department of Orthopaedic, Traumatology, and Rehabilitation, International Islamic University Malaysia, Kuantan, Malaysia
[2]National Orthopaedic Centre of Excellence for Research and Learning (NOCERAL), Department of Orthopaedic Surgery, Universiti Malaya, Kuala Lumpur, Malaysia
[3]Department of Orthopaedics, Ara Damansara Medical Centre, Shah Alam, Malaysia



This is an open-access article distributed under the terms of the Creative Commons Attribution License, which permits unrestricted use, distribution, and reproduction in any medium, provided the original work is properly cited

Date of submission: 20th January 2025
Date of acceptance: 18th November 2025

ABSTRACT

Spontaneous osteonecrosis of the knee (SONK) is frequently underdiagnosed despite its significance in acute knee pain, especially among older adults. Early diagnosis is imperative for preservation of the affected joint and prevent progression to osteoarthritis. We present a case of a 58-year-old female who developed acute, severe knee pain without prior trauma. Initially misdiagnosed as osteoarthritis, her condition worsened despite repeated steroid injections and arthrocentesis. Magnetic Resonance Imaging (MRI) confirmed SONK, leading to total knee arthroplasty. This case illustrates the diagnostic challenges of SONK and emphasises early clinical suspicion and MRI as a critical differentiating tool from osteoarthritis. Treatment strategies should be tailored based on lesion severity, patient age and activity demand. Clinicians must maintain high suspicion for SONK in acute non-traumatic knee pain. Prompt MRI evaluation is important for early diagnosis and optimal management.

Keywords:
arthroplasty, insufficiency fractures, osteonecrosis

INTRODUCTION

Spontaneous osteonecrosis of the knee (SONK) typically presents with sudden-onset knee pain in older adults, particularly women, without trauma or secondary risk factors. Initially described by Ahlbäck, SONK was considered ischemic; however, recent evidence supports subchondral insufficiency fractures (SIF) as the initiating event, leading to localised osteonecrosis[1,2].

Distinguishing SONK early is vital. Unrecognised or untreated, SONK can rapidly progress, impairing quality of life and potentially necessitating arthroplasty[2]. In this context, magnetic resonance imaging (MRI) plays a pivotal role by identifying subchondral bone oedema and fractures prior to irreversible joint damage. Early recognition allows less invasive treatment, potentially preserving joint function[1].

This case is notable for an initial MRI consistent with pre-collapse disease that was treated as degenerative osteoarthritis, subsequent late presentation with tibial subchondral collapse and tricompartmental osteoarthritis, documented osteoporosis, and objective, long-term functional gains following total knee arthroplasty. The report underscores the importance of early MRI-based diagnosis and timely, stage-appropriate management[1-5].

CASE REPORT

A 58-year-old woman with hypertension and dyslipidemia presented with one-year history of acute onset severe medial left knee pain, swelling and instability. The stabbing pain, aggravated by walking and climbing stairs, impaired daily activities and sleep. She required walking aid during ambulation. Visual analogue score (VAS) was 8. No symptoms of infection or autoimmune disease were present, and there was no history of trauma, steroid use, or alcohol intake.

One year earlier, she sought treatment at another centre. MRI then showed gross effusion, florid marrow oedema of the medial femoral condyle and tibia plateau, medial meniscus bucket handle tear with degenerative changes of the medial joint compartment (Fig. 1), reported as suspicious of infective process. However, aspiration and blood investigations excluded infection, autoimmune or

Corresponding Author: Azlina Amir Abbas, National Orthopaedic Centre of Excellence for Research and Learning (NOCERAL), Department of Orthopaedic Surgery, Faculty of Medicine, Universiti Malaya, 50603 Kuala Lumpur, Malaysia
Email: azabbas@um.edu.my

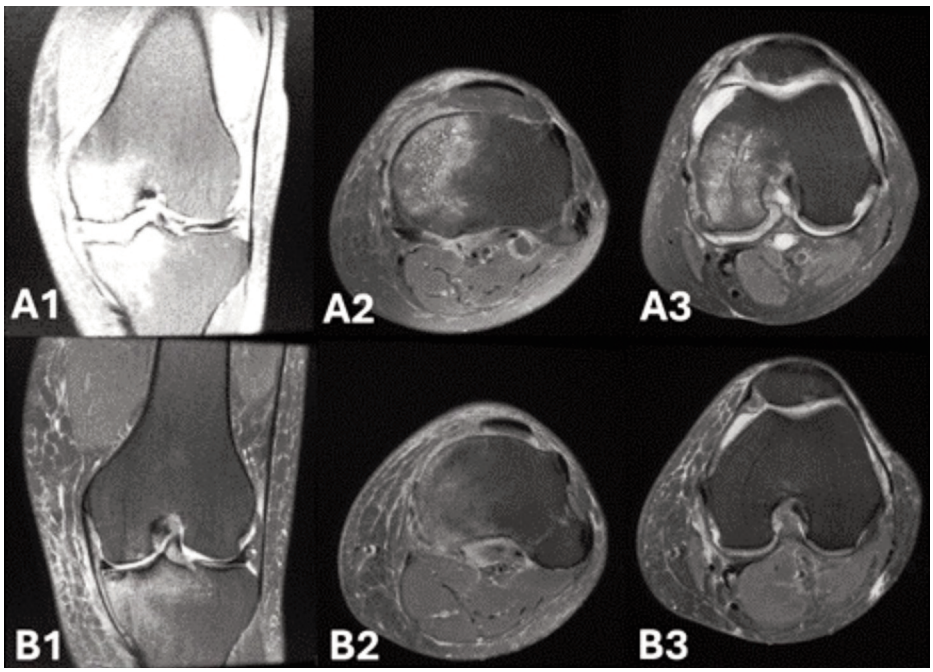

Fig. 1: Serial MRI findings of the left knee. (A1-A3) Initial MRI demonstrating florid bone oedema in medial femoral condyle and medial tibial plateau. (B1-B3) MRI a year later shows resolution of bone oedema.

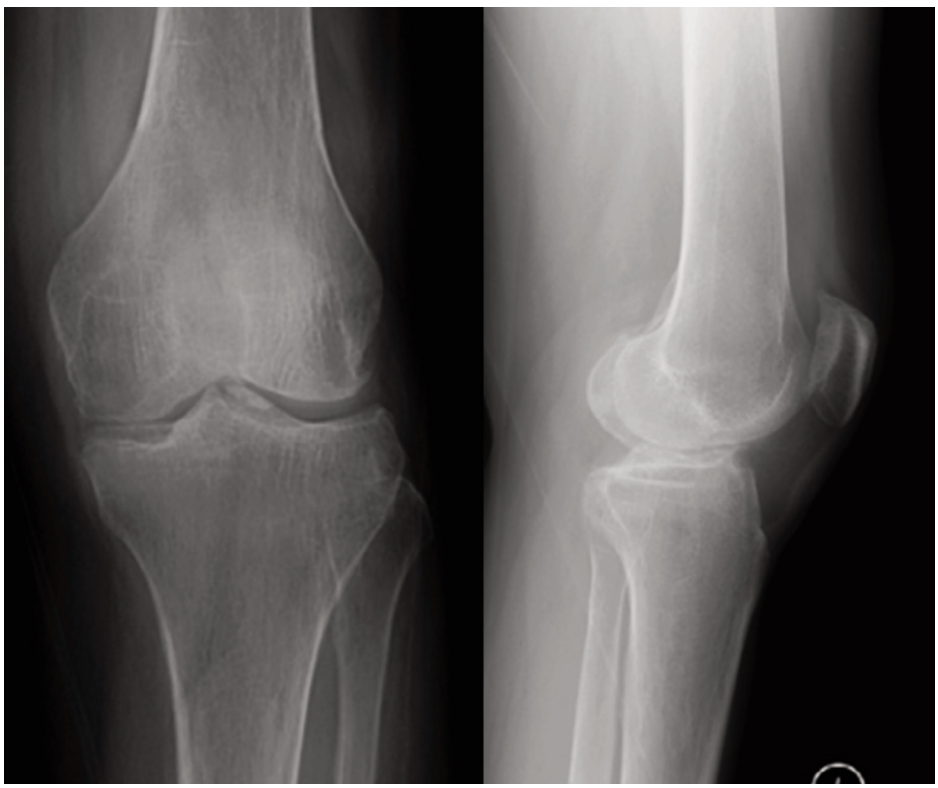

Fig. 2: Pre-operative plain radiograph showing arthritic changes and collapse of the medial tibial plateau.

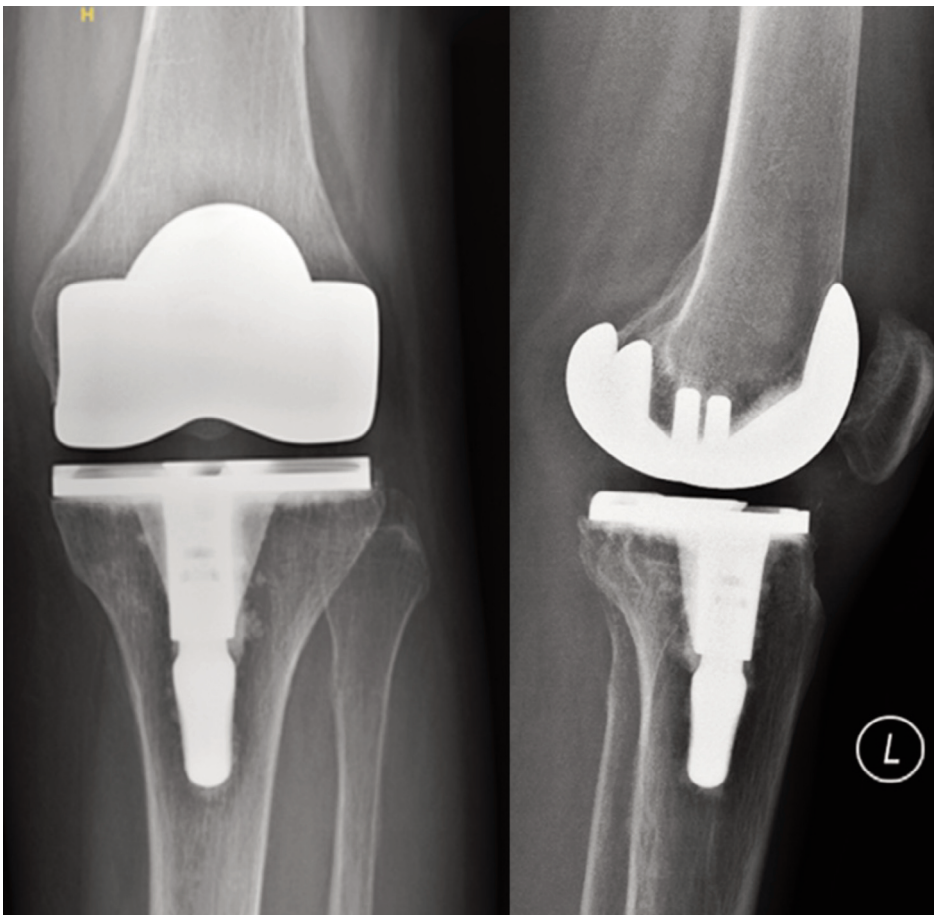

Fig. 3: Plain radiographs 18 months post total knee arthroplasty.

inflammatory arthritis. Consequently, she was diagnosed with early osteoarthritis and treated with multiple arthrocentesis and two intra-articular steroid injections over three months, without relief. Symptoms worsened in the first four months, improved by six months, then progressed with instability. She sought second opinion from us one year after onset.

On examination, she was obese, walked with antalgic gait. The left knee was varus with minimal effusion. There were medial femoral condyle and proximal tibial tenderness and Grade 2 lateral collateral ligament laxity. Range of motion was 0 – 105°. Radiograph showed medial tibial subchondral bone collapse (Fig. 2). Repeated MRI at our centre demonstrated resolution of bone oedema and tricompartmental osteoarthritic changes, most severe medially (Fig. 1). Bone mineral densitometry (BMD) revealed osteoporosis; she was prescribed bisphosphonates, calcium and Vitamin D. After the diagnosis of SONK and a discussion of conservative and surgical options, she chose total knee arthroplasty (TKA) for definitive relief and to regain early mobility, given her work commitments. Intra-operatively, arthritic changes corresponded with imaging. Histopathology showed osteoarthritic changes with osteoporosis, healing microfractures, and chronic inflammation. Cultures were negative.

Post-operatively, she was able to ambulate without walking aid. VAS improved from 8 to 2 at 12 months and 0 at 18 months post TKA. Knee Injury and Osteoarthritis Score (KOOS) improved from 37 to 68 at 12 months and 75 at 18 months. Radiograph at 18 months post TKA is shown in Fig. 3.

DISCUSSION

Spontaneous osteonecrosis of the knee (SONK) was first described by Ahlbäck in 1968 as a peculiar radiolucent lesion of the subchondral bone in the medial femoral condyle, primarily in women over 50 years of age with atraumatic acute medial-sided knee pain[2]. The acute presentation differentiates SONK from osteoarthritis (OA) which develops and worsens gradually. Other differentials include the self-limiting subchondral insufficiency fractures (SIF) without necrosis, and osteochondritis dissecans typically seen in younger patients[1,2]. Risk factors include female sex, age, obesity, low BMD, and posterior meniscal root tear,[1,2] all of which were present in our patient. The medial femoral

condyle is most affected, with less frequent involvement of the tibial plateau (as in our patient), lateral condyle, or patella. Knee osteonecrosis is categorised as spontaneous (SONK), secondary (corticosteroids, trauma, radiation), or post-arthroscopic[4].

The exact aetiology of SONK is unclear. Once thought ischaemic, MRI and histology now suggest it arises from SIF with secondary localised osteonecrosis, explaining the acute presentation[1-3]. Steroid-induced osteonecrosis was unlikely here as MRI changes predated steroid injections. It is also more likely to occur with high doses and longer treatment duration. Instead, the injections may have worsened the condition by contributing to subchondral damage[4].

Early radiographs may be normal, causing delayed diagnosis. MRI is the investigation of choice, although findings might not be apparent in the initial few weeks. Early-stage is characterised by marrow oedema at the central weight-bearing aspect of the medial femoral condyle with intact articular cartilage[1-3,5]. These findings may mimic infection or other conditions such as transient bone marrow oedema syndrome, avascular necrosis, and inflammatory arthropathies. Clinical correlation and follow-up imaging are needed to differentiate. If initial MRI is inconclusive, repeat imaging is recommended when symptoms persist[1,2,5]. The initial MRI of our patient exhibited these and a medial meniscus tear (a predisposing factor for SONK), but without fracture or articular collapse likely indicating presentation at the pre-collapse phase. Bone marrow oedema typically regresses by the 5th month, with cystic changes appearing by the 7th month. The subchondral bone collapse phase shows a focal depression, and a fracture line filled with subchondral fluid. Late-stage disease shows subchondral collapse, articular surface irregularity, and secondary osteoarthritic changes[1-3]. Our patient presented to us late (a year after onset), correlates with the repeat MRI, and explains the histopathological findings of osteoarthritis, osteoporosis with healing microfractures[2,3].

Management varies according to disease stage and patient factors. Pre-collapse and lesions < 3.5cm^2 often respond favourably to conservative treatments such as partial weight-bearing, analgesics, and pulsed electromagnetic therapy. Bisphosphonates were thought to be able to delay bone resorption while revascularisation occurred in SONK, but recent evidence have shown conflicting results[2-5]. Giannini *et al*[3] and Jadhav *et al*[5] described successful conservative treatment of patients with SONK in their reports. Had our patient been diagnosed with SONK at her initial presentation a year prior, she could have benefitted from conservative measures.

Failed conservative cases, post-collapse, lesions > 3.5cm^2, or with advanced osteoarthritic changes require surgery. Depending on severity and patient age, options include joint-preserving-procedures (e.g. core decompression, osteochondral graft, osteotomy), or arthroplasty. TKA offers long-term outcomes in end-stage SONK comparable to primary osteoarthritis, suggesting that our patient's favourable course at 18 months is likely to continue over the longer term[2-4].

In conclusion, SONK is a potential cause of knee pain that may be missed or misdiagnosed. Early diagnosis and treatment are crucial to halt disease progression and delay the need for invasive interventions. Orthopaedic surgeons should suspect SONK when symptoms persist despite therapy, and early MRI is essential for timely diagnosis.

This report provides comprehensive documentation of disease progression, supported by serial imaging from an early pre-collapse phase at another centre to late-stage collapse on follow-up MRI., objective outcomes (VAS/KOOS to 18 months), and integration of current prognostic criteria from the literature. The main limitations of this report include the unavailability of the first MRI (which was done in another centre) dataset and measurement details (such as lesion size and depth), which limited comprehensive temporal comparison.

CONFLICT OF INTEREST

The authors declare no potential conflict of interest.

REFERENCES

1. Malghem J, Lecouvet F, Vande Berg B, Kirchgesner T, Omoumi P. Subchondral insufficiency fractures, subchondral insufficiency fractures with osteonecrosis, and other apparently spontaneous subchondral bone lesions of the knee-pathogenesis and diagnosis at imaging. *Insights Imaging.* 2023; 14(1): 164. doi: 10.1186/s13244-023-01495-6
2. Serrano DV, Saseendar S, Shanmugasundaram S, Bidwai R, Gómez D, D'Ambrosi R. Spontaneous Osteonecrosis of the Knee: State of the Art. *J Clin Med.* 2022; 11(23): 6943. doi: 10.3390/jcm11236943
3. Giannini S, Mazzotti A, Arceri A. Osteonecrosis of the knee: a concise review of the current literature. *Int J Bone Frag.* 2022; 2(1): 11-5. doi: 10.57582/IJBF.220201.011
4. Sondur S, Vj G, Das SP. Osteonecrosis of the Knee: The Unintended Consequence of Steroid Abuse. *Clin Med Res.* 2024; 22(1): 37-43. doi: 10.3121/cmr.2024.1855
5. Jadhav S, Dhaniwala N, Dudhekar U, Dadlani M, Awasthi AA. Spontaneous Osteonecrosis of Knee: A Case Report. *Cureus.* 2023; 15(9): e44587. doi: 10.7759/cureus.44587

Cite this article:

Nasuruddin MH, Selvaratnam V, Ayob KA, Abbas AA. Missed Spontaneous Osteonecrosis of the Knee: A Case Report. *Malays Orthop J.* 2026; 20(3): 91-5. doi: 10.5704/MOJ.2611.012