doi: https://doi.org/10.5704/MOJ.2611.013

Non-Union of Medial Malleolus with Growth Arrest of Medial Distal Tibia and Lateral Overgrowth of Distal Fibula in a Child: A Case Report

Kishanraj HK, MMed Ortho, **Sulaiman AR,** MMed Ortho, **Mohd EF,** MMed Ortho, **Munajat I,** MMed Ortho, **Irfan AA,** MD

Department of Orthopaedics, Universiti Sains Malaysia, Kubang Kerian, Malaysia

This is an open-access article distributed under the terms of the Creative Commons Attribution License, which permits unrestricted use, distribution, and reproduction in any medium, provided the original work is properly cited

Date of submission: 04th June 2025
Date of acceptance: 24th October 2025

ABSTRACT

Non-union of a non-ossified bone poses diagnostic challenges. We present a paediatric case of unossified medial malleolus non-union, causing progressive ankle varus deformity. This case highlights the diagnostic challenges of non-union of unossified medial malleolus, complicated by medial distal tibial physeal arrest, distal lateral fibular overgrowth, and failure of fibular epiphysiodesis. A 6-year-old Malay boy presented with progressive varus deformity and instability of the right ankle following an open fracture five months before that. Initial assessment revealed a varus ankle with medial arrest of the distal tibia physis and overgrowth of the distal fibular. Initial management involved a supramalleolar osteotomy, epiphysiolysis of the tibial growth plate, and K-wire fixation of the incidentally discovered medial malleolus non-union. Over the subsequent three years, the deformity recurred intermittently, accompanied by progressive distal lateral fibular overgrowth and failure of fibular epiphysiodesis using a staple in combination with plate and screw. Repeated interventions, including guided growth and valgus osteotomy of the fibula, were unsuccessful in preventing recurrent deformity. At the age of nine years, with radiographic visualisation of the medial malleolus ossification centre, non-union was suspected and confirmed with a varus stress view radiograph of the ankle. The condition was effectively treated through bone grafting and stable fixation of the medial malleolus, in combination with distal fibular epiphysiodesis and a supramalleolar osteotomy.

Keywords:
paediatric ankle fracture, medial malleolus, physeal injury, non-union, fibular lateral overgrowth

INTRODUCTION

The medial malleolus plays a significant role in preserving normal tibiotalar joint mechanics. Fractures here can reduce the joint contact area, elevate contact pressures, and cause instability. In children, such fractures can cause physeal bar formation, leading to progressive varus angulation, limb length discrepancies, and ankle arthrosis if untreated. Fracture may be invisible in the unossified distal tibia epiphysis. The medial malleolus begins ossifying by age 8 and completely ossifies by age 12 in boys[1]. We present this case to highlight challenges in diagnosing non-union of unossified medial malleolus fracture, its sequelae, and management.

CASE REPORT

This 6-year-old boy, presented with progressive ankle deformity and inability to bear weight, following an open ankle fracture due to a motorcycle spoked wheel injury five months earlier. He had normal motor and social development. Examination revealed varus deformity, a healed scar, and limited ankle motion. Radiographs showed ankle varus with lateral malleolus overgrowth and obliquity of the distal tibia physis (Fig. 1a). A CT scan revealed a physeal bar at the medial distal tibia growth plate (Fig. 1b and 1c). The patient underwent tibia and fibula supramalleolar corrective osteotomy, medial tibial epiphysiolysis, and K-wire fixation of the medial malleolus non-union identified via intra-operative arthrogram (Fig. 1d). After studying the coronal and sagittal CT-scan images, the epiphysiolysis was performed through medial window using high-speed burr under image intensifier and direct visualisation with a headlight. The defect was filled with bone wax.

Corresponding Author: Abdul Razak Sulaiman, Department of Orthopaedics, School of Medical Sciences, Universiti Sains Malaysia, Kubang Kerian, 16150, Kota Bharu, Kelantan, Malaysia
Email: drarazaks@gmail.com

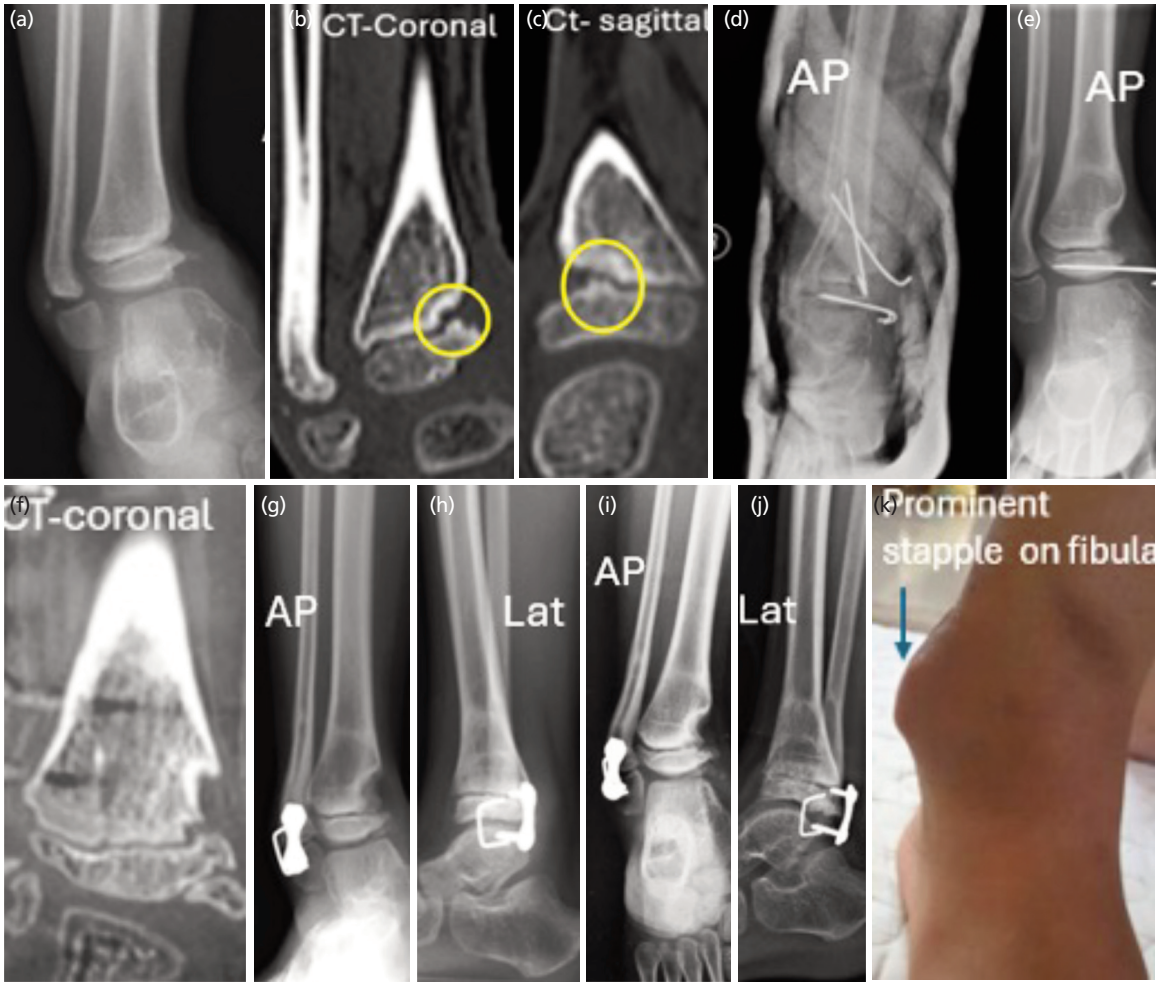

Fig. 1: Series of radiographs, Ct-scan images and photo; (a) Anterior posterior radiograph showing ankle varus with an unossified medial malleolus. (b and c) CT-scan at 6.4 years old demonstrating an anteromedial distal tibia physeal bar. (d) Radiograph after the first corrective osteotomy at 6 years. (e) Radiograph at 7 years showing recurrent fibular varus. (f) CT at 7 years confirming there is absence of physeal bar on distal tibia. (g and h) Radiograph at 7.5 years following guided growth. A plate placed posteriorly and the staple over the anterolateral aspect of fibular physis. (i and j) Radiographs showing persistent fibular varus indicating a failed guided growth and a horizontal Harris growth-arrest line in the tibia indicating a successful physeal bar resection. The fibular staple appears subtle in place radiographically due to its posterolateral position. (k) Clinical photograph at 7.8 years showing prominent fibular staple, consistent with mechanical failure.

A year later, at age of 7-year-old, varus deformity recurred with distal fibular overgrowth despite no recurrence of the medial physeal bar on CT-scan (Fig. 1e and 1f). Following the finding, guided growth of the lateral malleolus with plate and staple as well as K-wire removal of medial malleolus were performed (Fig. 1g and 1h). However, six months post-operative, varus deformity recurred (Fig. 1i) with stapple migration (Fig. 1j and 1k). Subsequently at age of 7.9 years old, distal tibia-fibula osteotomy was repeated. Tibia was held with K-wires, while distal fibula osteotomy was held with plate and screw fixation, including screw transfixion of the distal fibula physis (Fig. 2a).

Eight months later (Age 8), the screw transfixing the fibula physis broke (Fig. 2b). At this time, the fibular growth plate was oblique, indicating lateral fibular physeal overgrowth, and the secondary ossification centre of the medial malleolus became visible. The gap between the ossified medial malleolus and the tibia was interpreted as incomplete ossification of the medial malleolus, not non-union. Shortly thereafter, fibula and tibia fixation were removed, and two cancellous screws were inserted to arrest fibular growth (Fig. 2c). Six months later, at age of 9 years old, varus deformity with fibular lateral overgrowth recurred with evidence of epiphysiodesis failure (Fig. 2d, 2e and 2f). Medial malleolus non-union was suspected and confirmed by worsening varus on stress radiograph (Fig. 2g).

Definitive surgery included distal tibia and fibula supramalleolar osteotomy via a midline incision. The medial malleolus was approached anteriorly. Bone graft from the iliac crest was packed through a limited incision under fluoroscopy, a screw provided compression, and a wire prevented rotation. Epiphysiodesis of the lateral malleolus

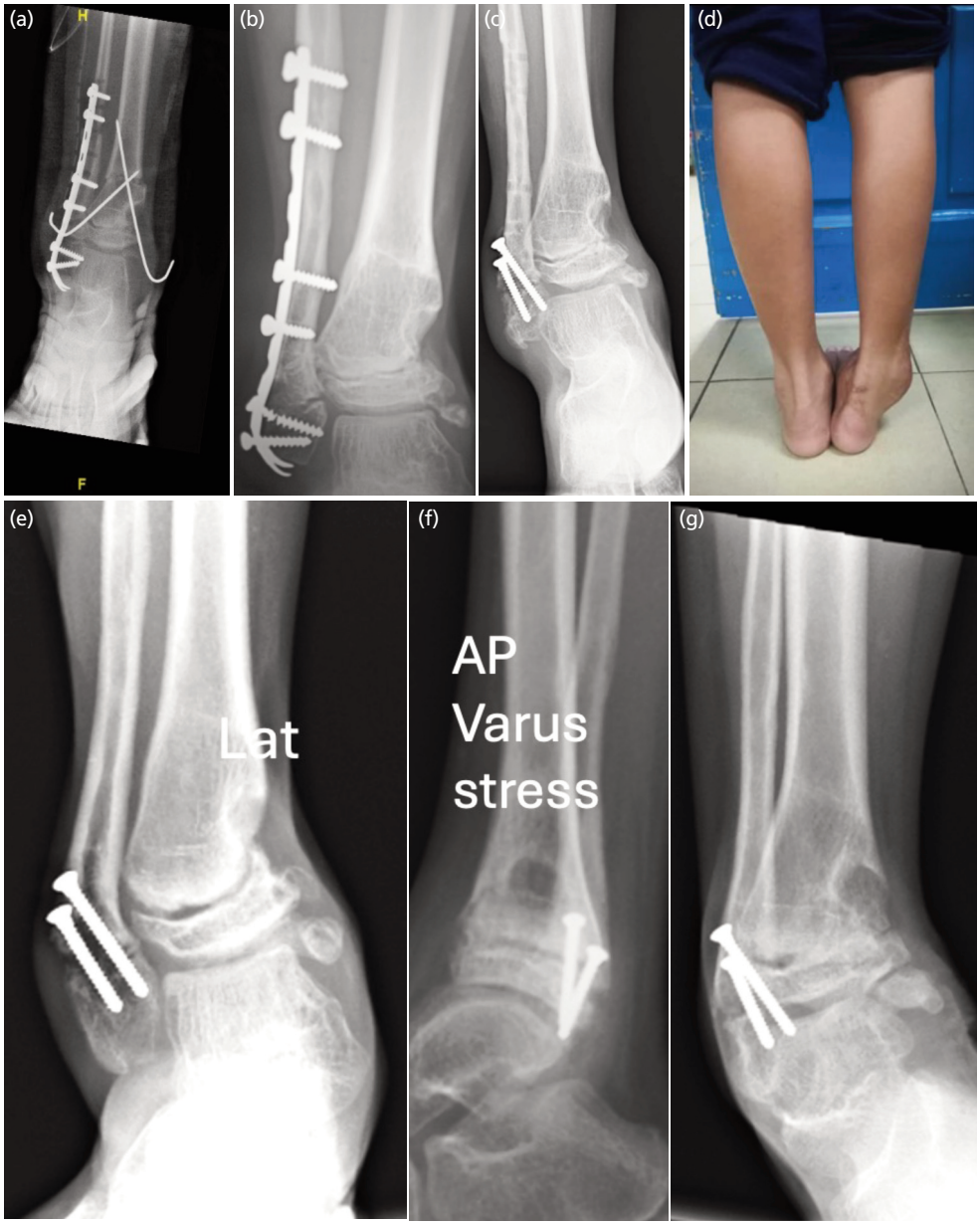

Fig. 2: (a) At 8 years, post-operative radiograph showing tibial osteotomy fixed with K-wire and fibular osteotomy held with a plate, a screw transfixing distal fibula growth plate aiming for epiphysiodesis of fibula growth plate. (b) At 8.7 years, broken fibular transphyseal screw with lateral overgrowth, indicating failed epiphysiodesis; separation of the ossified medial malleolus from the tibia interpreted as a new ossification centre. (c) Radiograph, a month later shows a straight fibula with a revision transphyseal screw and a clear ossification of the medial malleolus. (d – g) Serial imaging and photo at 9 years old; (d) clinical photograph depicting the ankle deformity at the same time point. (e) Radiograph with screw loosening, fibular angulation, ankle varus, oblique fibular physis, and increased medial malleolus-tibia distance, (f) radiograph showing an oblique distal tibial physis with distal angulation, (g) varus stress radiograph: reduced medial clear space between the medial malleolus and tibia; the apparent lack of space medially at the tibial physis is likely due to physeal obliquity rather than true closure.

was repeated by multiple drill holes through a stab wound (Fig. 3a and 3b). A year later (age 10) the medial malleolus united (Fig. 3c and 3d), and he resumed all activities without pain or limited ankle range of motion. Review at age of 12 showed medial malleolus remain united with horizontal ankle (Fig. 3e and 3f) and the recent review at age 15 showed no recurrence (Fig. 3g and 3h).

DISCUSSION

Medial malleolus fracture in children is associated with a high rate of physeal bar formation. It is explained by the occurrence of SH type III fractures in 55.1% and SH type IV fractures in 44.9% of 78 medial malleolus fractures in children between the ages of 5.5 and 13.9 years[2]. They found that inadequate reduction led to physeal bar formation. Luhmann *et al* demonstrated that a displacement of 2mm in

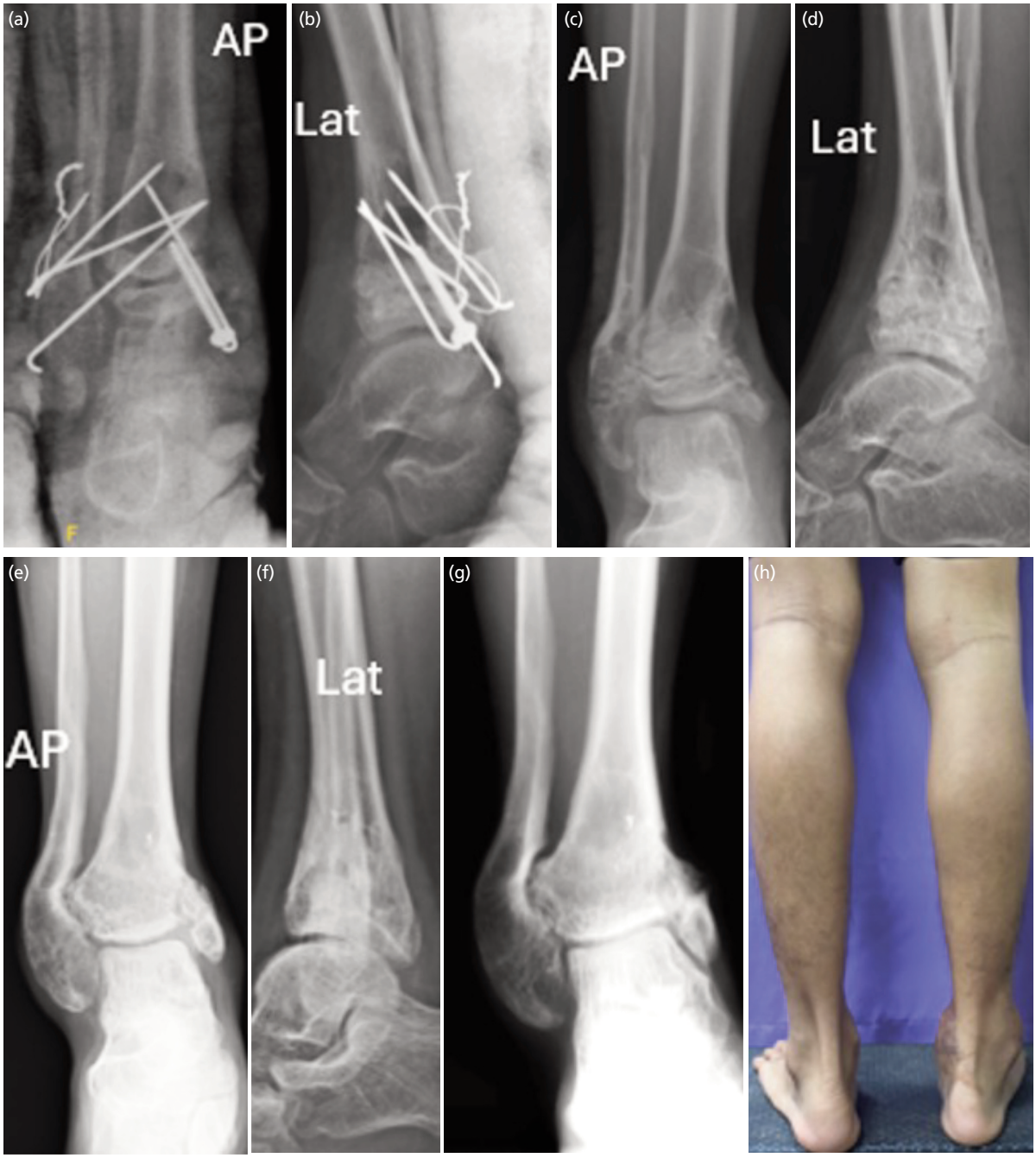

Fig. 3: (a and b) At 10 years, radiographs following supramalleolar distal tibial osteotomy and fibular osteotomy, stabilized with K-wires and tension- band wiring. The medial malleolus with bone graft is secured to the tibia using screw fixation and an anti-rotational K-wire. (c and d) At 10.5 years, radiograph showing union of the ossified medial malleolus and a straight fibula without any retained fixation. (e and f) At 12 years, radiographs demonstrating the medial malleolus remains united, the fibular head appears relatively enlarged, and the ankle alignment is neutral. At 15 years, (g) radiograph shows the medial malleolus remains united with slight ankle tilt, (h) clinical photo shows no recurrent ankle deformity overall.

medial malleolar fracture is considered unacceptable, as the concept of 'remodelling' does not apply to these fracture patterns[3]. Our patient developed progressive varus deformity five months post-injury due to medial distal tibial physeal arrest and instability from medial malleolus non-union, which also accelerated lateral malleolus growth via distraction forces[4], causing early deformity.

In this patient, the physeal bar was resected through a proximal window to release growth plate tethering and restore longitudinal growth. Realignment osteotomy redistributed weight-bearing forces, reducing medial physeal compression and improving balance. Effectiveness was evidenced by the horizontal Harris Line in (Fig. 1d).

We think the recurrence of deformity, despite successful medial physeal bar resection, resulted from medial malleolus non-union that causes loss of the medial buttress of the ankle, leading to varus instability that distracts the distal fibula, which can result in distal fibular lateral overgrowth and failure of guided growth. The distraction was so significant that even epiphysiodesis of lateral malleolus could not be achieved with plate and screw fixation until the medial malleolus non-union was treated. This situation resembled the chronic non-union of distal fibular physeal fracture described by Ponton *et al*[5].

Initial fixation using a single K-wire for the medial malleolus in this patient was insufficient to achieve union. The delay in diagnosing non-union was due to incomplete ossification of the distal tibia epiphysis, which typically extends to the medial malleolus between the ages of 7 and 8[1]. The secondary ossification centre appears in males between 8 and 11 years[2]. At age 9, the ossification centre seen in this patient was misinterpreted as a normal gap between it and the distal tibial epiphysis (Fig. 2b), delaying the diagnosis. A high index of suspicion is crucial, especially with varus ankle instability. Early varus stress dynamic radiograph can aid diagnosis, while MRI may help assess non-union in open physes and unossified medial malleoli when metal is absent. In paediatric patients, stable fixation is crucial not only for promoting osseous healing but also for preventing recurrent mechanical instability that could disrupt normal growth dynamics[5].

Success in treating the non-union was attributed to stable fixation and bone grafting. Given the confined anatomy, physeal proximity, and scarred tissue, a limited incision under image intensifier was used to pack the graft. One screw provided compression, and a wire-controlled rotation. Ponton *et al* also reported using autologous bone graft in paediatric medial malleolar reconstruction, highlighting its efficacy and limitations, including donor site morbidity, graft resorption, and challenges in incorporating grafts near growing physes[5].

This case highlights the diagnostic challenges of unossified medial malleolus non-union, complicated by distal tibial physeal arrest, and fibular lateral overgrowth and failure fibular epiphysiodesis. Non-union was suspected upon ossification and confirmed via varus stress view. Treatment involved physeal bar resection, tibia-fibula realignment osteotomy, and bone grafting with stable medial malleolus fixation.

CONFLICT OF INTEREST

The authors declare no potential conflict of interest.

REFERENCES

1. LaMont L, Ladenhauf HN, Edobor-Osula F, Bogner E, Do HT, Green DW. Secondary ossification centers in the development of the medial malleolus. *J Pediatr Orthop.* 2015; 35(3): 314-7. doi: 10.1097/BPO.0000000000000266
2. Abbot MD, Siebert MJ, Wimberly RL, Wilson PL, Riccio AI. Physeal Bar Formation After Pediatric Medial Malleolus Fractures. *Orthopedics.* 2024; 47(1): e33-7. doi: 10.3928/01477447-20230616-03
3. Luhmann SJ, Oda JE, O'Donnell J, Keeler KA, Schoenecker PL, Dobbs MB, *et al.* An analysis of suboptimal outcomes of medial malleolus fractures in skeletally immature children. *Am J Orthop (Belle Mead NJ).* 2012; 41(3): 113-6.
4. Voller T, Cameron P, Watson J, Phadnis J. The growth plate: anatomy and disorders. *Orthop Trauma.* 2020; 34(3): 135-40. doi: 10.1016/j.mporth.2020.03.006
5. Ponton E, Bakkai A, Courtemanche DJ, Cooper AP. Late Ankle Reconstruction in a Child with Remote Traumatic Medial Malleolus Loss: Clinical and Radiographic Outcomes. *Strategies Trauma Limb Reconstr.* 2022; 17(2): 131-5. doi: 10.5005/jp-journals-10080-1552

Cite this article:

Kishanraj HK, Sulaiman AR, Mohd EF, Munajat I, Irfan AA. Non-Union of Medial Malleolus with Growth Arrest of Medial Distal Tibia and Lateral Overgrowth of Distal Fibula in a Child: A Case Report. M*alays Orthop J.* 2026; 20(3): 96-100. doi: 10.5704/MOJ.2611.013