doi: https://doi.org/10.5704/MOJ.2611.014

Immediate Distal Nerve Transfer for Thenar Reinnervation Following Median Nerve MPNST Resection: A Case Report

Supichyangur K, MD, **Luarngjindarat S,** MD, **Bualuangngam T,** MD

Department of Orthopaedics, Rajavithi Hospital, Bangkok, Thailand

This is an open-access article distributed under the terms of the Creative Commons Attribution License, which permits unrestricted use, distribution, and reproduction in any medium, provided the original work is properly cited

Date of submission: 23rd June 2025
Date of acceptance: 14th December 2025

ABSTRACT

Malignant peripheral nerve sheath tumour (MPNST) is a rare and aggressive soft tissue sarcoma that may affect major peripheral nerves such as the median nerve. Wide surgical resection remains the mainstay of treatment but often results in significant functional impairment, especially when long segments of nerve must be removed. We report the case of a 49-year-old woman with high-grade MPNST of the right distal forearm involving the median nerve. She underwent wide excision, resulting in a 13cm nerve defect and resection of multiple flexor tendons. Immediate single-stage reconstruction was performed using sural nerve grafts, tendon transfers, and a distal nerve transfer of the motor branch of the abductor digiti quinti (ADQMB) to the thenar branch of the median nerve (TBMN). At 10 months post-operatively, the patient achieved functional thumb opposition (MRC Grade 5), with grip strength of 8 pounds on the affected side compared to 16.5 pounds contralaterally. No thenar muscle atrophy or loss of little finger abduction was observed. Although pulmonary metastases were detected seven months post-operatively, local control at the forearm remained stable. This case demonstrates that immediate ADQMB to TBMN transfer, combined with sural nerve grafting, is a practical and effective method for restoring thumb function after extensive median nerve resection. Early reinnervation may help preserve motor endplates and improve functional outcomes in selected patients undergoing radical oncologic nerve surgery.

Keywords:
abductor digiti quinti, distal nerve transfer, malignant peripheral nerve sheath tumour, median nerve, thenar muscle reinnervation

INTRODUCTION

Malignant peripheral nerve sheath tumour (MPNST) is a rare, aggressive soft tissue sarcoma often involving the extremities or trunk. Its poor prognosis is associated with factors including tumour size, depth, neurofibromatosis type 1 (NF1), margin status, and distant metastasis. Standard treatment involves wide surgical resection, while adjuvant radiation or chemotherapy remains controversial. When involving major nerves, surgery can severely impair limb function. Particularly in high median nerve resection, delayed axonal regeneration risks irreversible thenar muscle atrophy[1] due to prolonged nerve denervation is the cause of endplate degeneration. Distal nerve transfers, help reducing distance of axon regeneration and increasing chance of motor nerve recovery, such as abductor digiti quinti motor branch (ADQMB) to the thenar branch of the median nerve (TBMN)[2], have emerged as promising techniques for restoring thumb opposition in such settings. We report a case of single-stage wide MPNST resection and median nerve reconstruction using sural nerve graft and immediate ADQMB–TBMN transfer.

CASE REPORT

A 49-year-old woman presented with a 4×5cm painless mass at the volar distal forearm. She had a prior history of breast cancer and leiomyosarcoma, but no signs of NF1. MRI showed a heterogeneous, ill-defined mass involving the median nerve as shown in Fig. 1. Core biopsy confirmed high-grade sarcoma. Chest CT revealed a 0.3 cm pulmonary nodule; initial chemotherapy was deferred due to lack of definitive benefit. She underwent wide tumour resection including flexor tendons (all FDS, index FDP, FCR, FPL) and a 13cm segment of the median nerve.

For the surgical technique, the tendon reconstruction included brachioradialis transfer to FPL as a standard technique for restoring thumb IP flexion in high median nerve palsy, and side-to-side transfer of the index FDP to the middle FDP was chosen due to their similar tendon excursion. A sural nerve graft was harvested for bridging the

Corresponding Author: Kittiwan Supichyangur, Department of Orthopaedics, Rajavithi Hospital, 2 Phaya Thai Rd, Thung Phaya Thai, Ratchathewi, Bangkok 10400, Thailand
Email: Kittiwan_s@outlook.com

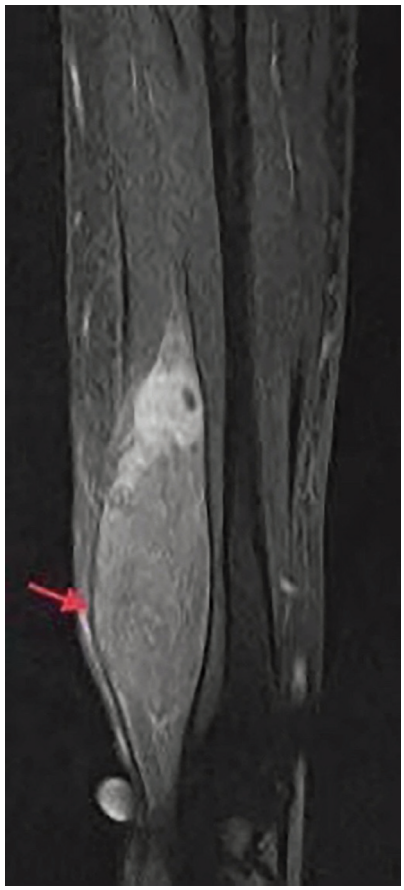

Fig. 1: MRI forearm sagittal plane in T1FS with Gad respectively demonstrated an ill-defined oval mass that involved the median nerve and abutted to surrounding flexor tendons with a heterogeneous enhancing pattern, perilesional edema and intra-tumoral lobulation.

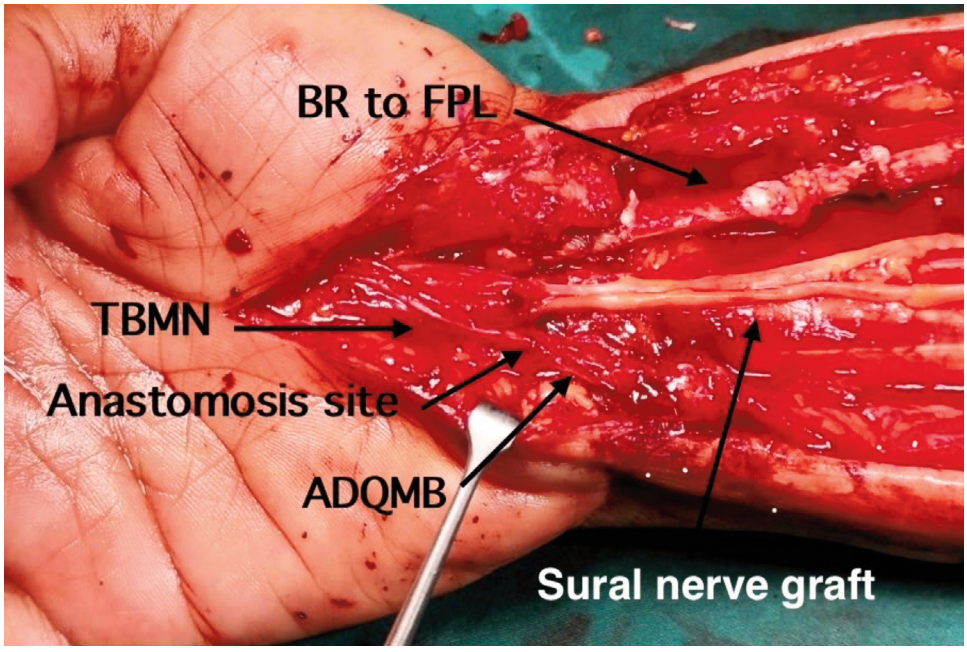

Fig. 2: BR was transported to FPL and index FDP was transferred to middle FDP, size of the sural nerve graft was 13cm. Proximal stump of median nerve was connected with distal stump by sural nerve graft, ADQMB was transposed to TBMN.



Fig. 3: At 10 months post-surgery, her affected thumb opposition was Grade 4 on the MRC muscle power scale.

13cm nerve gap. For thumb motor function, the motor branch of abductor digiti quinti (ADQMB) was identified and transferred to the thenar branch of the median nerve (TBMN), immediately after resection. Electrical stimulation aided precise nerve identification and confirmed its functionality. All repairs were done in a single-stage operation (Fig. 2).

For post-operative course, the forearm was immobilised in a dorsal slab for four weeks, followed by active hand therapy. Final histopathology confirmed high-grade MPNST with osteosarcomatous and chondrosarcomatous differentiation. Margin status was positive radially (R1 resection). As the tumour was abutting the radial artery, we discussed the options with the patient and decided to proceed with post-operative radiotherapy (66Gy/33fractions) rather than performing a tumour bed resection with vascular reconstruction.

Next, for the outcome, at two months, she demonstrated thumb opposition and active flexion of digits II–V. At six months, thumb and index flexion improved (MRC Grade 3); sensory loss persisted in radial digits without thenar atrophy. At 10 months, thumb opposition reached MRC Grade 4; grip strength of affected thumb was 8 pounds (vs. 16.5 contralaterally), Kapandji score was 8, and she could perform daily activities (Fig. 3). Little finger abduction remained symmetric. Unfortunately, pulmonary nodules progressed at 7 months, prompting initiation of chemotherapy.

DISCUSSION

MPNST carries poor prognosis, especially when margins are positive, or metastases occur early. Heterologous differentiation (e.g., osteosarcoma and chondrosarcoma) is rare but known to portend worse outcomes. Complete resection remains standard, but often comes at the cost of limb function. In high median nerve injuries, restoring thumb opposition is critical for hand utility. Traditional tendon transfers are effective but delayed.

Several studies support distal nerve transfers for faster motor recovery, Bertelli *et al*[2] proposed transferring the ADQMB to the TBMN to improve thumb pronation, thenar bulk, abductor pollicis brevis, and British Medical Research Council scores by 10 months post-op. Three-fourths of patients regained grasp and pinch strength, with no loss of little finger abduction.

Ozcelik *et al*[3] reported two female patients with high median nerve injuries from gunshots. Following nerve grafting, the motor branch of the first palmar interosseous (ulnar nerve) was transferred to the TBMN. At six months, Mehta scores were 21 and 20, with no noticeable adduction loss.

Power *et al*[4] reported a median nerve synovial sarcoma treated with distal nerve transfers post-resection. The fourth common digital nerve was transferred for sensation, and the ADQMB branch to TBMN for opposition. At 15 months, thumb opposition was Grade 4, with gradual sensory recovery. They concluded this technique is a reliable option.

Recently, Jerome[5] reported a 19-year-old patient with a 4-month-old high median nerve palsy, treated by transferring the adductor branch of the ulnar nerve to the TBMN, with sural nerve grafts bridging the gap, and by transferring the extensor carpi radialis nerve to the anterior interosseous nerve. At 10 months, thumb opposition was effectively restored.

Our case is different in performing this transfer immediately after tumour excision, within a single-stage reconstruction. The several advantages of immediate distal nerve transfer in large-gap major nerve resection, are achieving early nerve reinnervation to target muscle in order to reduce change of muscle atrophy and preserve motor end plate as much as possible, another reason is easy to identify recipient nerve at intra-operative period by nerve stimulation due to no Wallerian degeneration yet.

Importantly, transferring the ADQMB is functionally tolerable, with minimal donor deficit. In our patient, thumb function recovery was evident by 2 months, with significant functional use by 10 months. Little finger abduction remained intact. Combining early nerve grafting with distal transfer offers both sensory and motor recovery potential, even in extensive nerve loss. Unfortunately, our patient had a positive oncologic margin, necessitating adjuvant radiotherapy and close surveillance for local recurrence.

In conclusion, this case demonstrates that immediate distal nerve transfer (ADQMB–TBMN) combined with sural nerve grafting is feasible and functionally effective following wide resection of median nerve MPNST. This approach may improve outcomes in patients requiring extensive oncologic nerve resections with clear margins at the time of surgery by preserving key motor function and minimising delay-related atrophy.

CONFLICT OF INTEREST

The authors declare no potential conflict of interest.

ACKNOWLEDGEMENTS

The authors are grateful to the staff in the Division of Medical Research, Department of Research and Technology Assessment, Rajavithi Hospital, for their supportive assistance.

REFERENCES

1. Yoshimura K, Asato H, Jejurikar SS, Cederna PS, Urbanchek MG, Kuzon WM Jr. The effect of two episodes of denervation and reinnervation on skeletal muscle contractile function. *Plast Reconstr Surg.* 2002; 109(1): 212-9. doi: 10.1097/00006534-200201000-00032
2. Bertelli JA, Soldado F, Rodrígues-Baeza A, Ghizoni MF. Transfer of the Motor Branch of the Abductor Digiti Quinti for Thenar Muscle Reinnervation in High Median Nerve Injuries. *J Hand Surg Am.* 2018; 43(1): 8-15. doi: 10.1016/j.jhsa.2017.08.00
3. Ozcelik IB, Yildiran G, Mersa B, Sutcu M, Celik ZE, Ozalp T. A novel nerve transfer: The first palmar interosseous motor branch of the ulnar nerve to the recurrent motor branch of the median nerve. *Injury.* 2020; 51 Suppl 4: S81-3. doi: 10.1016/j.injury.2020.02.119
4. Power HA, Fox IK, Kahn LC, Mackinnon SE. Restoration of sensation and thumb opposition using nerve transfers following resection of a synovial sarcoma of the median nerve. *J Hand Surg Glob Online.* 2019; 1(3): 185-9. doi: 10.1016/j.jhsg.2019.05.004
5. Jerome JTJ. Adductor Branch of Terminal Divisions of the Ulnar Nerve Transfer to the Thenar Motor Branch in a High Median Nerve Palsy: A Case Report. *JBJS Case Connect.* 2023; 13(1). doi: 10.2106/JBJS.CC.22.00704

Cite this article:

Supichyangur K, Luarngjindarat S, Bualuangngam T. Immediate Distal Nerve Transfer for Thenar Reinnervation Following Median Nerve MPNST Resection: A Case Report. *Malays Orthop J.* 2026; 20(3): 101-4. doi: 10.5704/MOJ.2611.014