

## A Painful Click In The Knee In An Adolescent

<sup>1</sup>Rao M, <sup>2</sup>Nizlan NM, <sup>1</sup>Raymond YDK, <sup>1</sup>Silvaraju M

<sup>1</sup>Orthopaedics Department, Hospital Serdang, Jalan Puchong, 43000 Kajang, Selangor

<sup>2</sup>Orthopaedics Department, University Putra Malaysia, Jalan UPM, 43400 Serdang, Selangor

### INTRODUCTION:

Knee clicking without pain is common in a child. But if the click becomes painful, then further management is warranted. We present a case of a painful clicking knee in a young girl.

### CASE PRESENTATION:

10 year old girl presented with a clicking right knee, during flexion and extension since early childhood; however in the last 2 months, started to develop pain whenever the knee clicks. Onset of the pain was with a trauma to the knee during sports. There was no swelling, instability or any locking of the knee. Examination showed range of motion of 0-130<sup>0</sup> with a palpable click during flexion and extension. Tender on palpation of the lateral joint line.

MRI showed a discoid lateral meniscus with a tear in the anterior horn.

Diagnostic arthroscopy revealed incomplete type discoid lateral meniscus with tear at the anterior horn. The torn segment had flipped into the notch causing the clicking and pain. We proceeded to repair the torn anterior horn of the lateral meniscus. Only a small portion of the middle of the meniscus which showed fraying was shaved.

### RESULTS:

Post-op child had no more click and pain in the left knee.

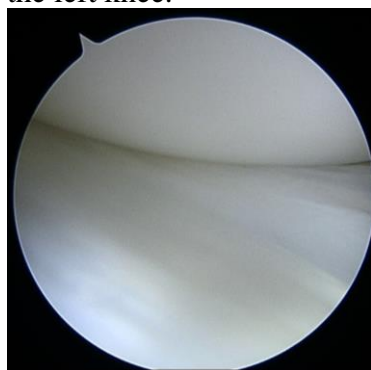


Figure 1:  
Discoid  
lateral  
meniscus

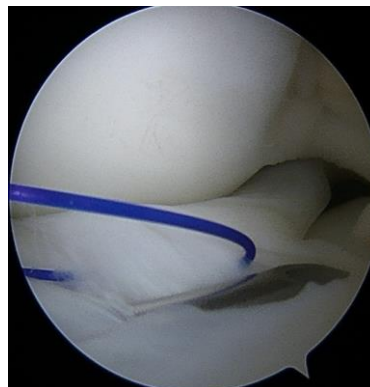

Figure 2:  
Anterior  
horn tear -  
repaired

### DISCUSSIONS:

An asymptomatic click in the knee can be treated with observation. The problem arises when the click produces pain, which should arouse the suspicion that there is a tear in the meniscus. A discoid meniscus is generally larger in size compared to a normal meniscus. This increases the area devoid of vasculature and may be prone to injury. The larger surface area of the discoid meniscus also provides a poorer attachment and is hypermobile leading to tears.

### CONCLUSION:

Symptomatic discoid meniscus frequently presents with meniscal tears. Meniscal repair as in our case provides a satisfactory outcome, while avoiding meniscectomy, which would be disabling in the young age group.

### REFERENCES:

1. The discoid meniscus: J Child Orthop (2007), Moshe Yaniv
2. Meniscopectomy for lateral discoid meniscus tears: Long-term results of 14 cases: B. Chedal-Bornu