

BODY OF SCAPULA FRACTURE MADE EASY WITH LATERAL APPROACH

Ab Aziz MA, Abdul Aziz MS, Mohd Noor F, Ibrahim MF, Syed Yahya SA

Department of Orthopaedic, Hospital Tengku Ampuan Najihah, Kuala Pilah, Negeri Sembilan.

INTRODUCTION:

Due to the multitude of fracture types amenable to a posterior approach, it is the operative approach of choice for the majority of cases. A less invasive surgical technique with minimal muscular dissection that still allows open reduction and internal fixation of complex scapula fractures, is desired.

REPORT:

A 237 years old gentlemen, alleged motor vehicle accident and complain of right shoulder pain & restricted movement. On examination, tenderness around right scapula, reduced range of motion of right shoulder. Distal pulses palpable and good circulation. Plain radiograph & CT scan with 3D reconstructed image showed fracture body of right scapula, extended superiorly. In operation theater, patient was placed on left lateral position with bump under right arm to keep elbow in flexion. The straight incision approximately 6-cm straight incisions were made, oriented over the glenoid neck or lateral border and over the location at the vertebral border or spine where the fracture exits. Laterally, the dissection was taken down to the deltoid fascia, which was divided in line with the deltoid fibers at its inferior edge. The deltoid was retracted cephalad, revealing the fascia overlying the external rotators. The fascia overlying the infraspinatus and teres minor was then divided in line with the muscular fibers exposing these muscles. Blunt dissection was used down to the lateral border between infraspinatus and teres minor, exposing the fracture site. Care was taken while retraction of the infraspinatus was performed at the lateral window so as not to tether or injure the suprascapular nerve that exits at the base of the acromion in the spinoglenoid notch. Articular congruency was restored under direct visualization and fixed with plating of right scapula, using locking reconstruction plate. The reduction was confirmed with intraoperative fluoroscopy. The fixation was stable,

intraoperatively, right shoulder able to flex until 180 degree. Patient was discharged well & advised with pendulum exercise.

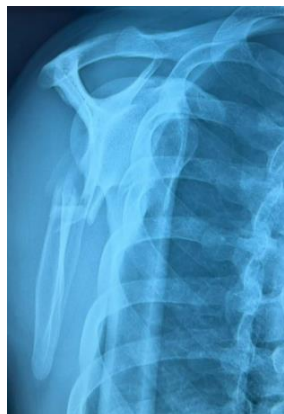

Figure 1: Superior approach of glenoid

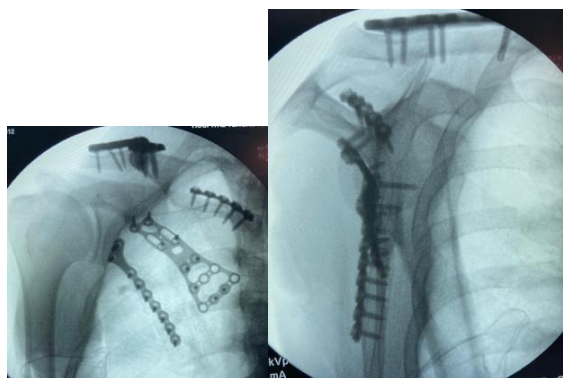


Figure 2: Locking reconstruction plate of glenoid

CONCLUSION:

This novel surgical approach to the scapula allows visualization of fracture reduction without an extensile incision or muscular or subcutaneous flaps and was associated with high functional scores.