

Preoperative serial casting in Charcot-Marie-Tooth disease

¹Ahmad Shuhiamy, Norsaidatul Nadriah; ²Pancharatnam Devarani; ³Zheng Yao Chin

¹Department of Orthopaedic Surgery and Traumatology, Universiti Teknologi MARA, Fakulti Perubatan, Kampus Sungai Buloh, Selangor, Malaysia, ²Department of Orthopaedic Surgery, University Malaya Medical Centre, Lembah Pantai, Kuala Lumpur, Malaysia. ³Hospital Taiping, Jalan Taming Sari, 34000 Taiping, Perak.

INTRODUCTION:

Charcot-Marie-Tooth (CMT) disease is one of the most prevalent hereditary nerve disorders and usually manifests with pes cavus deformity and ankle equinus in children.¹ However, there is a paucity of literature on the management of foot deformities in CMT patients.

REPORT:

A 12-year-old girl, with unknown medical illness, presented with 3 years history of progressive worsening of high-arched feet, difficulty walking, and pain at the plantar aspect of both feet after prolonged walking. She denies of any sensory changes in her upper and lower limbs. Otherwise, she had a normal developmental history and there was no family history of a similar condition.

Physical examination revealed that she had elevated medial longitudinal arch, hindfoot varus deformity, and ankle equinus, as shown in Figure 1. Both hindfoot varus were correctable to neutral position upon passive manipulation. Callosities were seen at the lateral border of both forefeet. Lower limb neurological examinations demonstrated MRC grade 4 for both ankle dorsiflexion and MRC grade 3 for both ankle eversion. Sensory and reflex examination of lower limbs were normal. Bilateral feet x-rays revealed markedly increased Meary's angle and calcaneal pitch. Nerve conduction study and electromyography showed mildly reduced amplitude and nerve conduction velocity of the common peroneal nerve, sural nerve, and median nerve. She was diagnosed with CMT and started on serial casting of the lower limbs. Subsequent follow-up showed marked improvement in the foot deformities. Once the foot deformities have improved, bilateral Achilles tendon lengthening, and plantar fascia release with additional tibialis posterior tendon transfer was performed. She was put on ankle-foot orthoses after 6 weeks

post-operatively. The foot deformities were corrected and she was able to resume her normal daily activities.

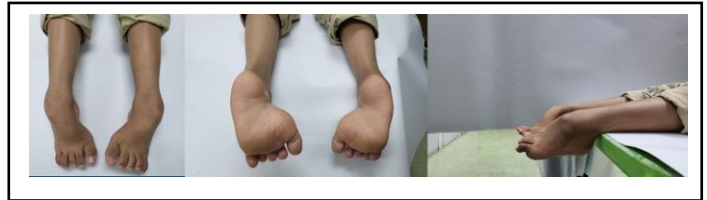

Figure 1: Foot deformities at presentation

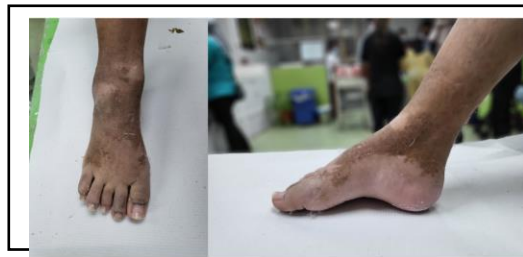

Figure 2: Right foot after serial casting

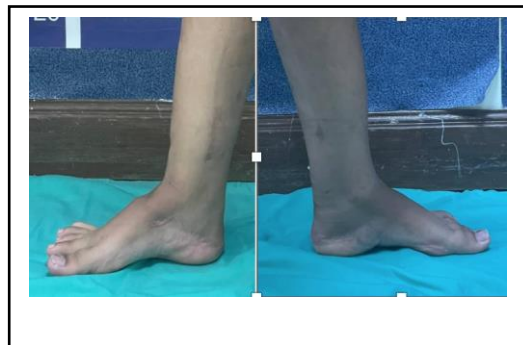


Figure 3: After serial casting and surgery

CONCLUSION:

In conclusion, serial casting can be used as a preoperative treatment for foot deformities in CMT patients.

REFERENCES:

1. Burns J at al. Symmetry of foot alignment and ankle flexibility in paediatric Charcot-Marie-Tooth disease. Clin Biomech (Bristol, Avon). 2012 Aug;27(7):744-7.