

An Uncommon Complication of Percutaneous Achilles Tenotomy for Congenital Talipes Equinovarus: Ankle Epidermoid Cyst

¹Khaw YC; ¹Muthu; ¹Mohd Firdaus Hafni Ahmad; ¹Zulkiflee Osman

¹Orthopaedic Department, Hospital Pulau Pinang, Jalan Resideni, 10990 George Town, Pulau Pinang

INTRODUCTION:

An epidermoid cyst is a benign encapsulated, subepidermal nodule filled with keratin material¹. However, epidermoid cyst is very rare to occur at ankle after percutaneous Achilles tenotomy. Only one case of epidermoid cyst in Achilles tendon has been reported in literature².

REPORT:

A 2-year-old girl presented with a slow-growing swelling of left ankle for one month. She had bilateral congenital talipes equinovarus (CTEV) and underwent bilateral percutaneous Achilles tenotomy 2 months ago prior to the swelling occurred. A 2 × 1 cm globular swelling at posterior left ankle, beneath the scar of tenotomy (Figure 1). It was firm, minimally tender, no mobile, no pulsatile, and not fluctuating. Excision biopsy surgery was done. Histopathology examination (Figure 2) revealed benign cystic lesion composed of fibrous wall lined by benign flattened keratinized stratified squamous epithelium and was diagnosed as ankle epidermoid cyst. After one year of follow up, she did not have recurrent swelling of ankle.

DISCUSSION:

An epidermoid cyst is a common type of benign cutaneous cyst with an epidermis-like epithelial wall, which is found commonly involve face, neck, periauricular area and upper trunk¹. It is rare to occurred at posterior ankle. It can occur after trauma or surgery². A literature search yielded only one case being reported; and is quite like our case². An ankle epidermoid cyst is a very rare complication of percutaneous Achilles tenotomy for CTEV. Therefore, a high index of suspicion is required to diagnose. Excision biopsy surgery needs to be done early as it can cause cosmetic and functional impairment¹.

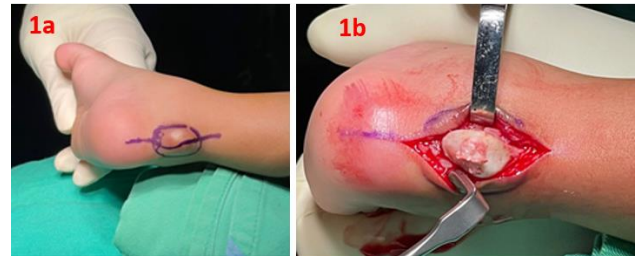


Figure 1: Swelling left ankle (1a). The swelling is whitish color, well demarcated and firm (1b).

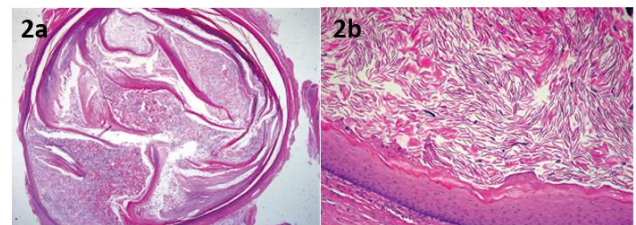


Figure 2: Histopathology examination showed the features of epidermoid cyst.

CONCLUSION:

A high index suspicion and early surgical intervention is an effective treatment of ankle epidermoid cyst.

REFERENCES:

1. Hoang VT et al. Overview of epidermoid cyst. *Eur J Radiol Open*. 2019 Sep 5;6:291-301.
2. Kotekar et al. "Epidermoid Cyst in Tendon Achilles Following Percutaneous Tenotomy in Congenital Talipes Equinovarus: A Case Report." (2019).