

Open Bimalleolar Fracture with Lateral Malleolus Fragment Buttonholing Tendon Achille

Syafiq MH, M, Anwar Hau

Orthopaedic And Traumatology Department Of Hospital Raja Perempuan Zainab 2 Kota Bharu

INTRODUCTION:

Bimalleolar ankle fracture is common occurrence. However, lateral malleolus fracture buttonholing to tendon Archilles is rare entity. There are few similar cases reported in english literature found⁽¹⁾. Here we share our experience managing such patient

REPORT:

Case of 25 years old gentleman, came to our casualty with complain of right ankle pain and open wound after axial force due to fall from 1meter high. He described that his foot in hyperabduction and pronated during impact. During surgical operative, fragment of lateral malleolus was totally missing from surgical field and was found trapped at the center tendon Archilles. Using 2 small reduction clamp the fragment was reduced by reversing the mechanism of injury, minimising the injury to the tendon archilles, fracture fixed using plate and tendon was repaired. Medial malleolus fracture then fixed using plate and screw Post operative radiographs were satisfactory. Patient was advise not to weight bearing. Post operative radiographs were satisfactory. Patient was advise not to weight bearing.

DISCUSSION :

The Lauge-Hansen classification system is one of the most widely used fracture classification systems. Base on patient history, it constant with Lauge-Hansen 3 the mechanism is pronation- abduction force, by using this we reverse the mechanism of injury and thus minimizing the injury to the tendon Archilles. Patient ankle was not protected because the injury to tendon <20%. Patient wasn't allow to weight- bearing. After 6weeks patient was allow full weight bearing, he had full range motion of

the ankle with no sign of weakening tendon Archilles. Fracture united well.

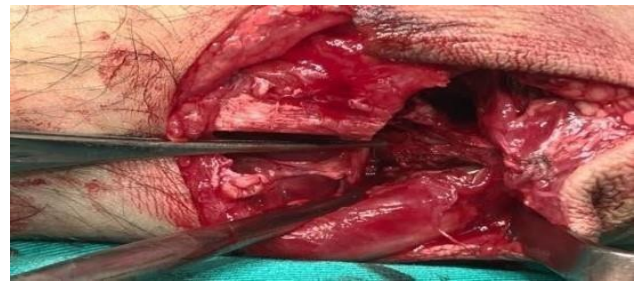


Figure 1: location of fragment at tendon archilles

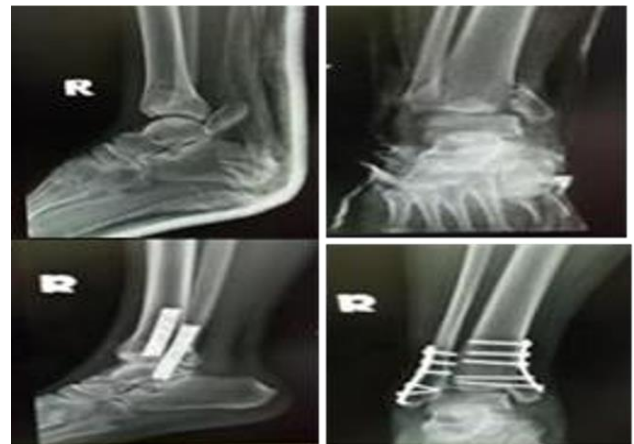

Figure 2: pre and post op plain radiograph

CONCLUSION:

Open bimalleolar fracture with injury to tendon Archilles is rare. Only few cases reported in online literature. Open reduction and internal fixation is compulsory with good post operative care to prevent unnecessary complication.

REFERENCES:

1. Lubin JW1, Miller RA, Robinson BJ, Blevins FT. Achilles tendon rupture associated with ankle fracture, Am J Orthop (Belle Mead NJ). 2000 Sep;29(9):707-8.