

## The Ever-Versatile Limb Reconstruction System: Hip Deformity Correction

<sup>1,2</sup>Nachimuthu Maniventhan, <sup>1</sup>Siti Nur Fudhlana Binti Ab Aziz, <sup>1</sup>Muhammad Syahid Bin Abd Jamal, <sup>1</sup>Mohd Azfan Bin Che Yusoff @Mohd Affandi, <sup>1</sup>Mohd Reza Bin Mohd Aridz, <sup>1</sup>Kamarul Al-Haqq Bin Abdul Ghani, <sup>2</sup>Mohd Hezery Bin Harun

<sup>1</sup>Orthopaedic Department, Hospital Tengku Ampuan Rahimah, Klang

<sup>2</sup>Orthopaedic Department, Hospital Sultan Abdul Aziz Shah, Universiti Putra Malaysia.

### INTRODUCTION:

Since reported by De Bastiani et al. back in 1987, the limb reconstruction system has greatly expanded its uses that still surprises us till today on its versatility. We present a case from our center that underwent deformity correction of his hip using this system with great outcome.

### REPORT:

An 18-year-old male with post-traumatic left hip slipped capital femoral epiphysis (SCFE), complicated by hip coxa vara and limb length discrepancy, resulting from a fall four years earlier. The patient underwent screw fixation then. Due to continued deformity and eager to return to sports, the young patient underwent valgus derotation and deformity correction using Limb Reconstruction System (LRS) for lengthening and realignment. Post operative follow up delightedly showcased patient with unhindered ambulation with promising radiological findings.

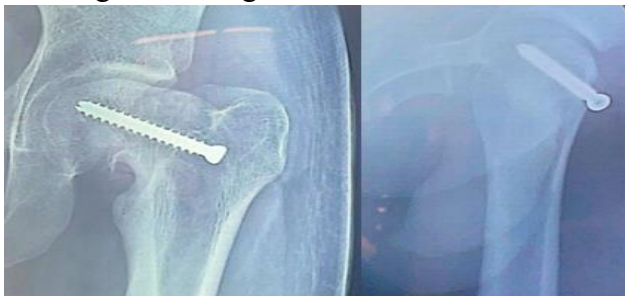

Fig 1: Pre operative x rays

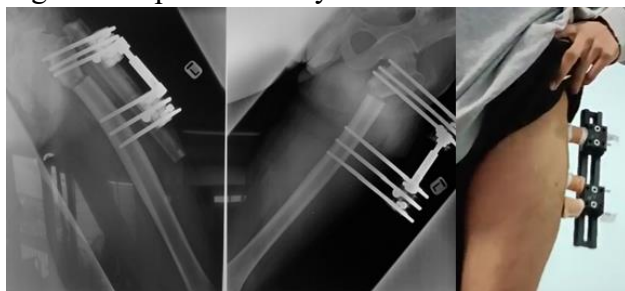


Fig 2: Post operative x rays and image

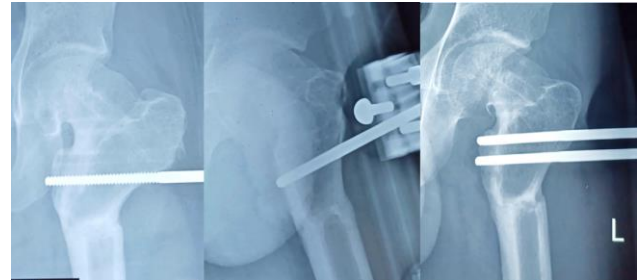

Fig 3: Follow up X Rays, showing callous

### DISCUSSION:

We employed this procedure to atraumatically manipulate the soft tissues together with the bone segments in order to obtain optimal restoration while preserving the bone biology. The effectiveness and versatility of this technique in treating hip deformities are highlighted, as it serves as an alternative for traditional plating techniques.

### CONCLUSION:

Valgus deformity correction and derotation using the LRS system is a promising approach for managing post-traumatic SCFE, offering a viable and effective alternative to traditional plating. Further studies are needed to confirm long-term outcomes and assess the applicability of this method across different patient populations.

### REFERENCES:

1. Buly RL, Sosa BR, Poultsides LA, Caldwell E, Rozbruch SR. Femoral Derotation Osteotomy in Adults for Version Abnormalities. *J Am Acad Orthop Surg.* 2018 Oct 1;26(19):e416-e425
2. Qin S, Ma X, Du H. Limb Reconstruction-A New Paradigm in Orthopedic Development. *Orthop Surg.* 2024 Sep;16(9):2109-2110