

Incarcerated Patella Dislocation: A Rare Case Report

Imran A; Azwan Z; Hakim H; Mardhiyah AN

Department of Orthopedics, Hospital Banting

INTRODUCTION:

Patellar dislocations occur when the patella is displaced from the trochlear groove.¹ These injuries often reduce spontaneously. However, rotational dislocation of patella with patella incarceration in fracture sites is rare in literature^{2,3} and this text discusses a case involving an irreducible patella with a lateral condyle femur fracture that require open reduction in the operating room.

REPORT:

Mr. N, an 18-year-old male, sustained a closed fracture of the left femur lateral condyle with patellar dislocation, following a motor vehicle collision. A trial of closed manual reduction in the emergency department was unsuccessful. CT imaging revealed the extent of the injury.

We performed an open reduction on the left patella with medial and lateral retinaculum repair. Intraoperatively, we found that the left patella was dislocated laterally and trapped between the fractured lateral condyle of the femur, with tears in both the medial and lateral retinacula. The dislocation was reduced, the tear repaired, and the left lateral condyle was fixed with screws. 8 weeks post-operatively, he is able to be allow to fully bear weight.

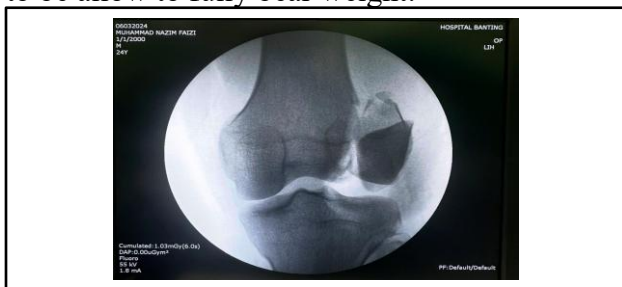

Figure 1: Intraop I/I image

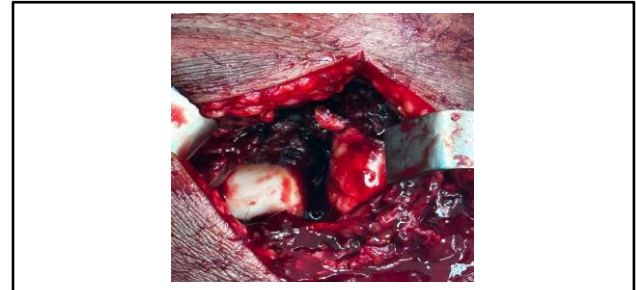


Figure 2 : Intraoperative image showing patella rotational dislocation and incarcerated into lateral femoral condyle fracture

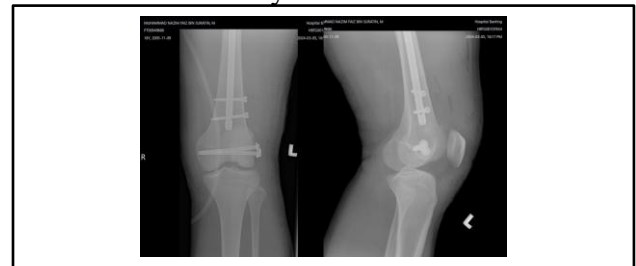


Figure 3 : Post operation check x-ray

CONCLUSION:

This case demonstrates how a lateral femoral condyle fracture causes the patella to be incarcerated, resulting in an irreducible situation. Surgeons must be vigilant about this condition, as it may lead to possible complications. CT imaging assists in evaluating the extent of impaction and aids in determining whether surgical intervention is necessary.

REFERENCES:

1. Brian R Moore, Joan Bothner. Recognition and Initial management of patella dislocation. (2024)
2. Balvinder Grewal, Devlin Elliott, Luca Daniele and James Reidy. Irreducible patella dislocation : A Rare case report and literature review. Oschner Journal (2016)
3. Chong YT, Chang CW. A Rare Case of Patella Rotational Dislocation and Incarceration in Femoral Condyle Fracture: A Case Report. *Malays Orthop J*. 2022