

## Osteo-Articular Reconstruction Surgery With Whole Femur Allograft After Infected Total Hip Arthroplasty And Acetabulum Plating: A Case Report

Ammar Manas MF, Abdul Muttalib AW, Suhana SB, Richford J  
Department of Orthopaedic, Hospital Segamat, Johor, 85000, Malaysia.

### INTRODUCTION:

Devastating complication following total hip arthroplasty are instability and infection which is challenging. Reconstruction of the acetabulum and recovering extensive bone loss at the proximal femur during revision hip arthroplasty is a major problem for orthopedic surgeon.<sup>1</sup> Thus, this is a case report of reconstruction surgery with whole femur allograft after infected total hip arthroplasty and acetabulum plating which produce a good outcome.

### MATERIALS & METHODS:

Case report

Mr. KO, 52yo, Malay gentleman, with no known medical illness, non-smoker; alleged motor vehicle accident in June 2012 sustaining left hip posterior dislocation with comminuted left acetabulum fracture. Open manual reduction and recon plating was done and x-ray showed good reduction. Six months after surger, the head of femur become avascular necrosis. Total hip arthroplasty was done in December 2012, however complicated with unstable hip and dislocated multiple times. Hence, patient had undergone three serial open reductions. First revision of Total Hip Replacement with constraint liner done in 2015. Later in 2016, he had persistent sinus discharge from the ilioinguinal wound and was treated as infected implant. Debridement of the hip was done and we had to remove the implant and shortened his proximal femur on December 2016 to eradicate the infection. At this stage, gentamicin antibiotic spacer was inserted at the acetabulum along with gentamicin-impregnated bead at the proximal femoral shaft. The patient was given Intravenous Cefotaxime for six weeks, then oral Rifampicin and Fusidic Acid for total six weeks until the infective parameters normalize. In January 2017 we proceed with second revision surgery. Acetabulum bone defect (Paprosky IIB) reconstructed and augmented with allograft femoral head and uncemented acetabulum cup. The femoral bone defect was about 15 cm (Paprosky IIIB) reconstructed with whole femur allograft using uncemented long femoral stem (265mm) using *allograft-prosthetic composite* technique. Long-stemmed femoral hip implant was fixed into the distal femur. The femoral construct

was secured with a cable plate and remaining allograft known as “kebab” technique.(Figure 1) . X-ray post-operative as shown and patient has good range of movement post fixation with no limb length discrepancy. It is still early to tell the surgery is successful. However, as our vigilant 3 months post- operative follow up there is no sign of infection and patient already ambulating with crutches.

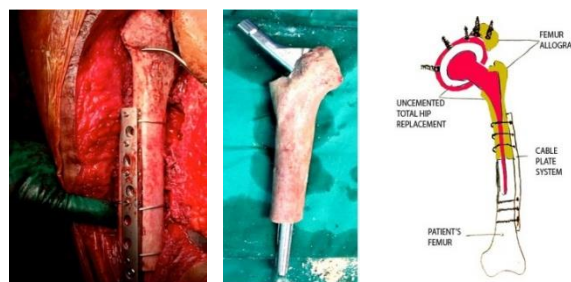

Figure 1: Picture and diagram showing *allograft-prosthetic composite* technique.

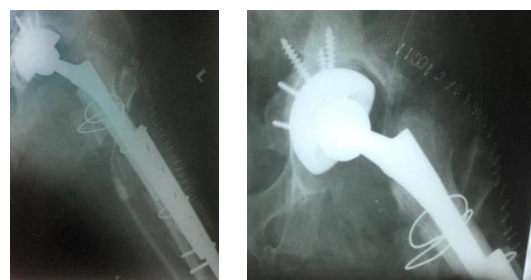


Figure 2: X-ray post-operative.

### DISCUSSIONS:

Whole femur allograft is an excellent option for this case as it provides anatomic scaffolding to replace bone loss together with its ability for osteogenesis and osteoinductive. However we need to weight the benefit versus the risk as allograft also has its drawbacks such as transmitting communicable diseases and potential excessive host immune response.<sup>1</sup> Therefore thorough preoperative discussion with patient is really necessary as the treatment plan is usually multi-step and we need to cater patient's expectation and surgeon's capability.

### CONCLUSION:

Whole femur bone graft is an excellent method in managing bone loss due to osteomyelitis post total hip replacement.

### REFERENCES:

1. Gross AE, Hutchison CR. Proximal femoral allografts for reconstruction of bone stock in revision arthroplasty of the hip. *Orthop Clin North Am* 1998;29:313-7.