

## Talar Body Fracture In Sagittal Plane With Successful Surgical Treatment: A Case Report And Short Review

Khaw YC, Tan CL, Or SY, Choo CY, Ong TK

Department of Orthopaedic, Hospital Seberang Jaya,  
Jalan Tun Hussein Onn, Seberang Jaya, 13700 Pulau Pinang, Malaysia.

### INTRODUCTION:

Fractures of talus are very rare accounting for 0.1 to 0.85% of all fractures<sup>1</sup>, talar body fractures in sagittal plane are still rarer. Fracture of talus body is a challenging injury to treat because talar body fracture is intra-articular fracture involving ankle joint and subtalar joint.

### MATERIALS & METHODS:

22 years old male's left foot stuck between forklift and wall during working, was send to accident and emergency department. On arrival, patient was alert, left foot was swollen until left ankle with abrasion wound and distal pulse is good. CT left ankle revealed fracture of talus body in sagittal plane which involves comminuted fracture talus dome, body and posterior process. Open reduction and screw fixation of left talus was done urgently.

### RESULTS:

At 3 months postoperative, left ankle range of motion is symmetrical to right ankle and painless. Patient is able to ambulate well without support. X-ray of left ankle showed joint is congruence, no collapse of talar body, no avascular necrosis and fracture is united.

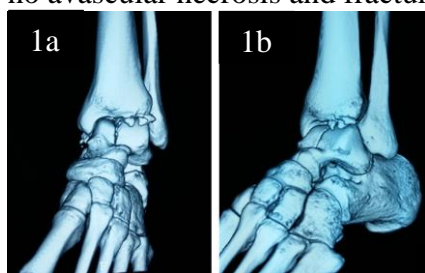


FIGURE 1:  
CT scan of  
Left Ankle

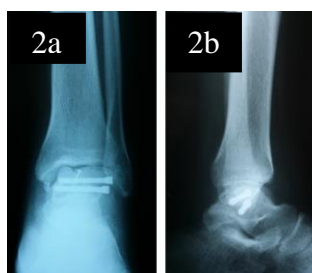

FIGURE 2:  
Postoperative  
X-ray

### DISCUSSIONS:

In our case, isolated fracture of talar body in sagittal plane is extremely rare because the fracture is not associated with malleolus or other tarsal bone fracture and is seldom reported. Inokuchi et al reported 9 cases of sagittal fracture of talar body among 206 cases talus fracture and the rate of occurrence was 4.4% of major talar fractures<sup>2</sup>. Talar body fractures have been described by Sneppen classification or Boyd and Knight classification<sup>1</sup>. Sneppen classified talar body fractures based on anatomic location, while Boyd and Knight classified talar body fractures according to plane of fracture and associated dislocation of ankle or subtalar joint. Anterolateral approach was used for open reduction and screw fixation of talus to achieve anatomical and stable reduction as talar body fracture is intra-articular fracture. Headless compression screws were used to fix the talar body fracture to prevent prominent hardware and to allow smooth ankle joint movement. Multiple small osteochondral fragments less than 0.5cm removed and the bone defect was filled by autologous bone graft. A large osteochondral fragment is fixed to talar body with mini screw to restore joint congruity.

### CONCLUSION:

Isolated fracture of talar body in sagittal plane is highly uncommon. Open reduction and internal fixation of talar body fracture by anatomical reconstruction is important to allow painless full range movement and able to carry out daily activities.

### REFERENCES:

1. Fortin PL et al. Talus fractures: evaluation and treatment. J Am Acad Orthop Surg. 2001; 9:14
2. Inokuchi S. et al. Fractures of the body of the talus in the sagittal plane. The Foot 1995: 143-147