

Carpometacarpal Joint Dislocations Of The Hand: A Case Report

¹Kow RY, ¹Ruben JK, ¹Zaharul-Azri MZ, ²Low CL

¹Department of Orthopaedic Surgery, Hospital Kuala Lipis, Kuala Lipis 27200, Malaysia.

²Department of Radiology, Hospital Kemaman, Kemaman, 24000, Malaysia.

INTRODUCTION:

Carpometacarpal joint (CMCJ) dislocation is a rare occurrence. They represent less than one percent of all injuries at the hand and wrist regions. We present a case of isolated carpometacarpal joint dislocations involving the middle, ring and little fingers.

CASE REPORT:

Mr R, a 29-year-old intravenous drug abuser and hepatitis C virus carrier, presented with pain and swelling at his dominant right hand one week after punching another person on the face with his right closed fist in an alleged physical fight. Plain radiographs of his right hand showed dislocations of the CMCJs involving the right middle, ring, and little fingers which were confirmed intra-operatively on image intensifier. An open reduction and fixation with Kirschner wires were done to stabilize the dislocated CMCJs.

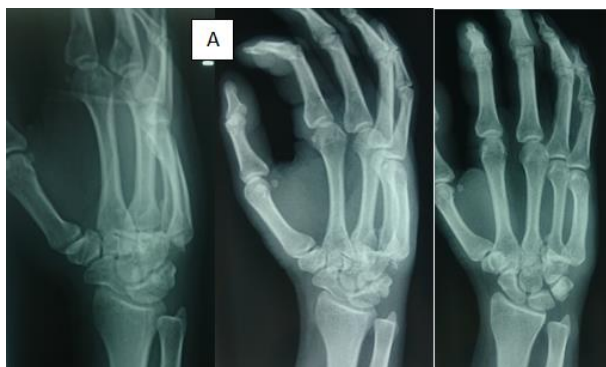

Figure A shows the plain radiographs of the affected right wrist.

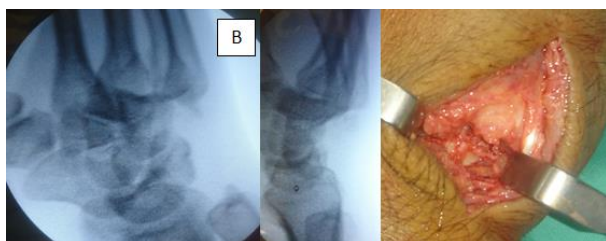


Figure B shows the dislocations of the CMCJs involving the right middle, ring and little fingers on the image intensifier and open reduction was done to reduce the affected joints.

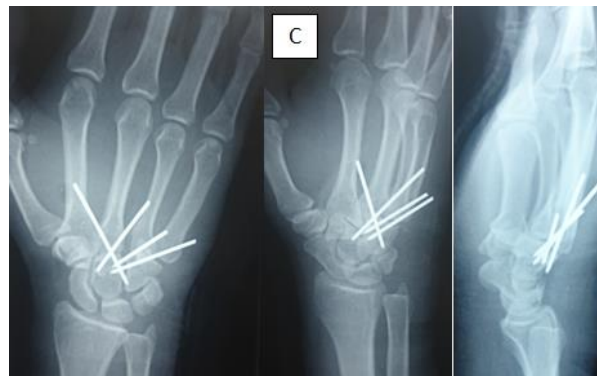


Figure C shows the post-operative plain radiographs of the right wrist with the affected CMCJs properly reduced and stabilized.

DISCUSSION:

Fist fight is the most common cause of carpometacarpal joint dislocation, followed by fall onto the hand. Carpometacarpal joint dislocations will cause disruptions of both the longitudinal and transverse arches of the hand. Delayed diagnosis and treatment will result in complications such as pain, reduced grip strength, and degenerative arthritis. Early diagnosis and prompt treatment will improve the functional outcome of the hand.

CONCLUSION:

A high index of suspicion should be raised based on the mechanism of injury to diagnose and treat carpometacarpal joint dislocation of the hand to improve the functional outcomes.

REFERENCE:

CYL Woon, KC Chong, CO Low. Carpometacarpal joint dislocations of the index to small fingers: Three cases and a review of the literature. *Injury Extra* 2006;37:466-472.