

Neglected Tuberculous Dactylitis With Severe Bony Destruction: A Case Report

Leong J, Tan TS, Ling LT

Orthopaedic Department, Hospital Sibul, Batu 5 ½, Jalan Ulu Oya, 96000 Sibul, Sarawak, Malaysia.

INTRODUCTION:

Tuberculous dactylitis is a rare presentation of extra-pulmonary tuberculosis and it constitutes less than 1% of skeletal tuberculosis^[1].

It typically affects proximal phalanges or metacarpal bones, most commonly involving a single bone^[2].

We're reporting a neglected TB dactylitis with severe bony destruction for 2 years, showed good outcome after completing anti-TB.

MATERIALS & METHODS:

A 23-year-old gentleman presented with right thumb swelling 2 years ago, excision biopsy done revealed Tuberculous infection. However, patient defaulted follow up before initiation of anti-TB chemotherapy.

He presented again after 2 years, with worsening swelling and pain over right thumb as well as significant constitutional symptoms (loss of weight & loss of appetite).

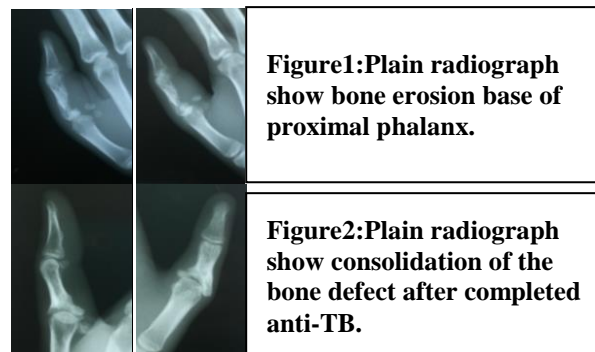
Examination show painful swelling over proximal phalanx of right thumb with no skin changes. Limited active range of motion of metacarpophalangeal joint (MCPJ) of right thumb. Gross instability noted over MCPJ especially upon varus stress.

Plain radiograph show bone erosion especially ulnar site of base of proximal phalanx including its articular surface.

Further workup revealed smear positive pulmonary tuberculosis. He was treated with anti-TB for 9 months with physiotherapy right thumb. Patient was follow up until treatment completed.

RESULTS:

Upon completion of anti-TB medication, functional status of right thumb showed a good improvement, which a painless, almost full range of motion MCPJ of right thumb achieved. His ESR normalized and plain radiograph revealed bony consolidation of previously bone defect with fairly congruent MCPJ preserved.



DISCUSSIONS:

Benkeddache reported TB dactylitis with joint involvement responded satisfactorily to anti-TB and conservative orthopaedic treatment and none of the case involved joints fused^[3].

Most of literature reviews advocating early diagnosis and early initiation of anti-TB. However, in our case, despite delay initiation of anti-TB for 2 years and with significant bony destruction and instability, a good outcome still can be achieved.

CONCLUSION:

Tuberculous dactylitis is a readily-treatable disease that is easily missed. Although TB dactylitis is rare, but the majority of lesions respond to conservative treatment, as anti-TB chemotherapy is the cornerstone in the management.

REFERENCES:

1. Subasi, Mehmet, et al. "Tuberculosis of the metacarpals and phalanges of the hand." *Annals of plastic surgery* 53.5 (2004): 469-472.
2. Ritz, N., et al. "Tuberculous dactylitis—an easily missed diagnosis." *European journal of clinical microbiology & infectious diseases* 30.11 (2011): 1303-1310.
3. Benkeddache, Yamina, and Howard Gottesman. "Skeletal tuberculosis of the wrist and hand: a study of 27 cases." *The Journal of hand surgery* 7.6 (1982): 593-600.