

A Tip Toe Gait: Benign Acute Childhood Myositis (BACM) - Case Report

Muhaimin NA, Zulfahmi F, Saifullah A

Department of orthopedic and Traumatology, Hospital Sultan Abdul Halim, Kedah, Malaysia

INTRODUCTION:

Benign acute childhood myositis (BACM) is a self-limiting disease characterized by sudden onset of muscle pain, more often calf pain, manifested by walking difficulty. Since many clinicians are not familiar with BACM, it is often misdiagnosed and interpreted as a more severe and complex disease. We report the case of a patient suffering from BACM presented with abnormal tip toe gait.

MATERIALS & METHODS:

We report a case of 1 year 10 month old girl presented with sudden acute onset tip toe gait. Her previous clinical history was not suggestive of any remarkable disease. Child had history of prodromal illness 1 week prior to the onset of abnormal gait. On presentation child was afebrile with normal vital signs. Child had wide based and toe-walking gait with bilateral ankle held in equinus position. Lower extremities strength and passive range of motion were normal. Mild tenderness over bilateral gastrocnemius soleus muscles. The rest of physical examination was unremarkable. Laboratory investigations showed slightly increase of Erythrocyte sedimentation rate and serum creatinine kinase level. Throat swab result no growth. All radiographic investigation were normal.

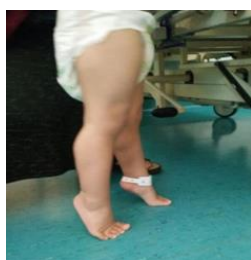


Figure 2: Day1
abnormal gait

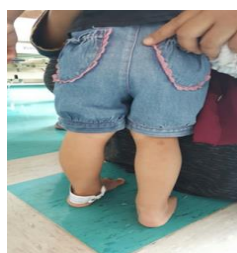

Figure 1 : Day3 No
residual abnormality

RESULTS:

Patient was admitted for observation and conservative management. On the third day patient condition rapidly improved. Child was able to walk normally without any residual abnormality.

DISCUSSIONS:

BACM classically affecting school-aged children with typical clinical presentation are bilateral calf pain. However in our case the age was less 2 years old and chief complaint was sudden onset of abnormal gait. Two gait-related abnormalities were reported by Mackay and colleagues to be characteristic of benign acute childhood myositis: a wide-based, stiff-legged gait and toe-walking. Both abnormalities were present in our patient. This abnormality is due to pain and discomfort in the lower extremities, commonly in the gastrocnemius-soleus muscle group bilaterally. The laboratory investigation in our patient were consistent with BACM, include a markedly elevated serum creatinine kinase level as well as increases in aspartate aminotransferase. The hallmark of BACM is its spontaneous and rapid clinical resolution within 1 week which occur in our patient.

CONCLUSION:

Recognition of this rare clinical entity is essential to prevent unnecessary invasive testing and hospital admission. In publishing this case report we hope to raise awareness of an infrequently encountered condition among clinicians.

REFERENCES:

1. Unnecessary diagnostic investigations in benign acute childhood myositis: a case series report. Neocleous C, Med J. 2012.
2. Benign acute childhood myositis--a rare cause of abnormal gait. Hall G, Schranz CI. Am J Emerg Med. 2014.
3. Benign acute childhood myositis: an alarming condition with an excellent prognosis! Santos JA, Albuquerque, J Emerg Med. 2014