

Disastrous Rare Complication Of Transforaminal Lumbar Interbody Fusion (TLIF) - Iatrogenic Lumbar Pseudomeningocele

¹Teh KH, ²Tan BB, ³Faruk NA, ³Wong CC

¹Medical Officer, Orthopedic Department, Hospital Sibul, Sarawak, Malaysia;

²Orthopedic Surgeon, University Malaysia Sarawak, Sarawak, Malaysia

³Orthopedic Surgeon, Hospital Umum Sarawak, Sarawak, Malaysia.

INTRODUCTION:

Lumbar pseudomeningocele is an uncommon complication of lumbar spine surgery. We describe a case of iatrogenic lumbar pseudomeningocele after a Transforaminal Lumbar Interbody Fusion (TLIF).

CASE PRESENTATION:

A 48 year old gentleman underwent open L4/5 TLIF for severe back and disabling left leg pain (L5 root), leaving him bed bound for 4 weeks. The surgery was uneventful but during the laminectomy, we noted a 5mm dural tear over the midline overlying the L4/L5 disc space. This was repaired with interrupted sutures using prolene 6/0, Post repair, valsava maneuver was done and there was no leakage at the repair site. Post operatively, there was evidence of cerebrospinal fluid in the drain and the patient developed severe postural headache. The patient was kept lying flat in bed for 7 days and drain removal done then with a suture applied over the drain site. However, the patient still complained of postural headache, nausea and vomiting upon sitting up and there was subcutaneous tissue swelling measured 12x5cm over the operation site. It was soft, fluctuant, not inflamed and increased in size when he was sitting. He was discharged home postoperatively after 4 weeks and was put on lumbar corset. He was unable to sit up for more than a few minutes because of the severe disabling headache. He continued to improve his sitting and standing tolerance and at 6 month follow up, the swelling and low intracranial pressure symptoms have resolved completely.

INVESTIGATIONS:

Magnetic Resonance Imaging (MRI) done at 5 months post operatively showed a posterior epidural and paraspinal collection with a thick

enhanced capsule extending from L4/L5 to S2 level, with no nerve roots seen within collection

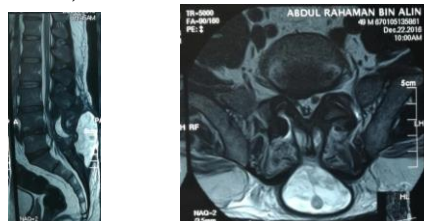


Figure 1 and 2: MRI Sagittal and Axial View

DISCUSSIONS:

Iatrogenic pseudomeningocele have been reported to be around 0.07%-2% of lumbar laminectomies and discectomies, more commonly seen in lumbar region because of the high intrathecal pressure and larger number of surgeries performed in this region¹.

Intraoperative dural tear with inadequate repair is known cause of postoperative pseudomeningocele formation which occurred in this patient. Immediate surgical repair is recommended for large pseudomeningoceles to prevent fistulous tract formation and subsequent infection.

CONCLUSION:

A large pseudomeningocele can be managed non operatively under close observation, expecting spontaneous resolution. Surgical exploration and repair were reserved only for those with worsening neurology, external fistula or infection.

REFERENCES:

- 1.Hawk MW, Kim KD. Review of spinal pseudomeningoceles and cerebrospinal fluid fistulas. Neurosurg Focus. 2000;9:e5.
- 2.Prince Solomon etc. Spontaneous resolution of postoperative lumbar pseudomeningocele:A report of four cases. Indian J Orthop. 2013