

A Good Functional Outcome Following Modified Pedicled Medial Gastrocnemius Muscle Flap For Open Proximal Third Tibia Fractures

¹Hanifah J, ²Lee SZ, ²Arman ZS

¹Department of Orthopaedic School of Medical Sciences, Universiti Sains Malaysia, Kubang Kerian, Kelantan

²Reconstructive Sciences Unit, School of Medical Sciences, Universiti Sains Malaysia, Kubang Kerian, Kelantan

INTRODUCTION:

Traumatic Gustillo Anderson grade IIIB open fracture of tibia poses difficulties as soft tissue reconstruction is usually required to cover soft tissue defects. However, in large soft tissue defects over proximal third of leg, the use of standard surgical approach for medial gastrocnemius flap showing difficulty to cover the whole area of exposed tibial bone and patella tendon.

MATERIALS:

We prospectively reviewed functional outcome of a 19-year-old-boy with fracture proximal 3rd of tibia associated with exposed tibia bone and patella tendon (9x2 cm and 6x3 cm respectively) (Figure 1). He initially managed with wound irrigation, antibiotic, wound debridement and external fixator. Then, he underwent soft tissue reconstruction with modified pedicle gastrocnemius flap 3-weeks later after adequate wound bed preparation.

SURGICAL TECHNIQUES:

The medial gastrocnemius muscle is separated from the median raphe and transected distally near the myotendinous junction about 8 cm from calcaneal Achilles tendon insertion. Few modifications are performed to increase the arc of rotation of the flap for wider wound coverage. Firstly, the epimysium of the muscle was scored with parallel lines.¹ Secondly, incision was extended proximally to facilitate dissection till the head of the medial gastrocnemius muscle at the medial condyle and the origin is detached, taking into great care to preserve the vascular pedicle.² Thirdly, to achieve extended coverage, the distal muscle is splitted longitudinally with prior intraoperative handheld doppler ultrasound to identify the course of the intramuscular perforators³ (Figure 2A&2B). The muscle surface was covered with skin allograft and was then skin grafted two weeks later.

RESULTS:

At five months, post-operatively, radiographic evidence of fracture union was achieved and complete weight bearing at the affected limb was allowed. The wound healed with good

aesthetic appearance. The patient also regained full knee range of motion, comparable to opposite site.

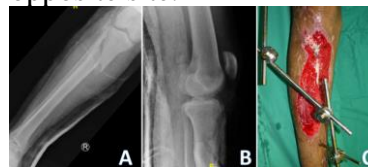

Figure 1: Injury (A) anteroposterior and (B) lateral radiographs demonstrating comminuted fracture of proximal third right tibia. Exposed tibia bone and patella tendon (C)

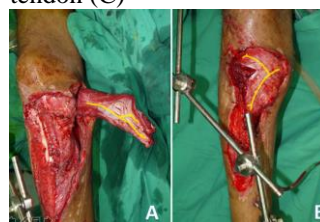


Figure 2: Local vascular anatomy of medial gastrocnemius flap marked with yellow marker (A), the distal part of medial gastrocnemius muscle is splitted longitudinally to increase arch of rotation and coverage to cover both exposed tibia and patella tendon (B)

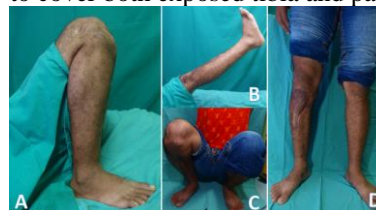

Figure 3 (A-D) : Good functional outcome on follow up 5 months post trauma with full range of motion knee flexion and extension

DISCUSSIONS:

Soft-tissue defects along the proximal third of the tibia often are effectively treated in many cases with a pedicled medial gastrocnemius muscle flap because of the relative ease of surgery, reliability of vascular pedicle, the width of the muscle, and minimal functional donor-site morbidity. In this case, we used a non-classical approach to the medial gastrocnemius muscle as described before. This non-classical approach increase arch of rotation of the flap to cover wider area of the soft tissue defect as in our case.

CONCLUSION:

The modified pedicled medial gastrocnemius is a safe, short, easy and reliable surgical option for the reconstruction of soft tissue defects over proximal third of tibia.