

# The Double-Edged Sword: Bisphosphonates Use And Atypical Fractures Of The Femur, A Case Series

Gomez DN, Kumar CS, Khirusman Y

Department of Orthopaedic Surgery, Pusat Perubatan University Malaya, Jalan Lembah Pantai, Kuala Lumpur, 59100, Malaysia

## INTRODUCTION:

The age-specific incidence rates of hip fractures in patients who were above 50 years old in Malaysia are 88 per 100,000 for men and 218 per 100,000 for females which has proven to be a significant public health challenge. As a result of this, consumption of medications to prevent and treat osteoporosis has been on the rise.<sup>1</sup> Several studies and case reports have shown that there is an associated increase in risk of atypical femoral shaft fractures with prolonged bisphosphonate use, and on the other hand there also have been large randomized control trials that report the risk of atypical fracture of the femur associated with bisphosphonate use as being very low, even in patients who received bisphosphonates for up to 10 years. These trials however had limitations of a small number of events and large confidence intervals.<sup>2</sup>

## METHODS:

We report a case series of 4 atypical femur fractures in patients who have had prolonged bisphosphonates consumption.

## DISCUSSIONS:

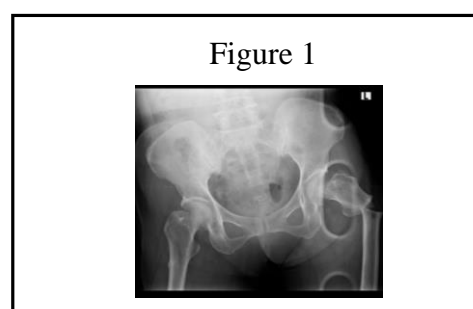
Bisphosphonates have been widely used for the treatment of osteoporosis, and the occurrence of atypical femoral shaft fractures secondary to this has been extensively reported with very varying results.<sup>2,3</sup> The American Society for Bone and Mineral Research (ASBMR) defined atypical femur fractures as those that fulfill all the criteria below; fractures distal to the lesser trochanter to just proximal to the supracondylar flare, no history of trauma or minimal trauma (defined as fall from standing height), and transverse or short oblique fractures.<sup>2</sup>

A telltale sign of these fracture is that it begins with a cortical beaking at the lateral cortex of the femur with an incomplete lucent line across the lateral cortex which eventually progresses to include the medial cortex over time.<sup>2</sup>

Our case series comprises of 4 femur fractures which occurred in 3 separate patients

(including 1 patient with a bilateral femur fracture) over the age of 50 who have been on prolonged bisphosphonate therapy that have been successfully treated. All the reported cases fulfill the ASBMR criteria for atypical femur fractures including beaking of the lateral cortex.

Figure1: Radiograph showing cortical beaking of the lateral cortex of the right and atypical subtrochanteric left femur fracture



## CONCLUSION:

The femur radiographs of patients on prolonged bisphosphonate therapy presenting to us with history of thigh pain, without history of trauma should be evaluated with a high index of suspicion. These x-rays have distinct radiographic features that should not be missed and appropriate counter measures should be taken to prevent further morbidity.

## REFERENCES:

1. Lau, E., Lee, J., Suriwongpaisal, P. et al. Osteoporos Int (2001) 12: 239. doi:10.1007/s001980170135
2. Dennis, MB. et al N Engl J Med (2010) 362:1761-1771
3. Tarun, PJ. et al Indian J Radiol Imaging. 2012 Jul-Sep; 22(3): 178–181.